

Telmisartan protects from myocardial ischemia/reperfusion injury via down regulation of the inflammatory response and apoptosisNajah R. Hadi ¹, Fadhil G. Al-Amran ², Maitham G Yousif ³, suaad T. zamil ⁴**Abstract**

Myocardial ischemia and reperfusion (I/R) injury is known to occur on restoration of coronary flow after a period of myocardial ischemia. In this study, we investigated the effects of Telmisartan in I/R injury and apoptosis. In this study, we investigated the effects of Telmisartan in I/R injury and apoptosis. Mice are subjected to 30 min ischemia followed by 120 min reperfusion through ligation of descending coronary artery (LAD). Mice treated with Telmisartan (0.5mg/kg, via IP injection) significantly attenuated I/R-induced increases of myocardial TNF- α , IL-1 β , IL-6 and markedly increased myocardial Bcl-2 protein expression. Furthermore, Telmisartan significant protective effect against myocardial I/R injury. Our data concluded that Telmisartan reduces inflammatory reaction associated with I/R injury induced by LAD ligation in addition to its reduction for cardiac injury and apoptosis induced by ischemia reperfusion.

Keywords: Telmisartan; Ischemia/reperfusion; cTn-I; Pro-inflammatory cytokine; Apoptosis

*Corresponding Author: Najah Hadi: drnajahhadi@yahoo.com

¹Department of Pharmacology and Therapeutics, College of Medicine, Kufa University

²Department of Surgery, College of Medicine, Kufa University
Kufa, Iraq.

³College of Science, Al-Qadesiya University

⁴Humanitarian and scientific studies University College, An Najaf, Iraq

Received September 30, 2016; Accepted February 25, 2017; Published March 22, 2017

Copyright © 2017 NH. *et al.* This is article distributed under the terms of the Creative Commons Attribution License (<http://creativecommons.org/licenses/by/2.0>), which permits unrestricted use, distribution, and reproduction in any medium, provided the original work is properly cited.

Introduction

Myocardial tissue TLR4 plays a major role in mediating myocardial injury following cold ischemia and reperfusion through up-regulation of MCP-1. Ischemia is a process that occurs when the demand for oxygen exceeds the available supply, most commonly as a result of inadequate blood flow [1]. Restoration of coronary blood flow (reperfusion) by using pharmacological or mechanical interventions following acute myocardial ischemia considered an essential for the salvation of viable myocardium. Paradoxically, reperfusion itself can causes cell damage and cell death mostly by initiating a localized oxidative burst and regional inflammatory response, referred to as “reperfusion injury” [2]. There is Cumulative evidence suggests that Ang II is a major contributor to cardiomyocyte (CM) apoptosis and left ventricular (LV) dysfunction after acute reperfused MI. Importantly, blockade of the Ang II type 1 receptor (AT1R) limits CM apoptosis and LV dysfunction after acute reperfused MI. Apoptosis is a regulated form of cell death that can potentially be a good approaches for therapeutic intervention to stop the loss of cardiac cells; experimental studies have shown that apoptosis arises as a widespread feature in cardiac diseases like ischemic heart disease and congestive heart failure [4].

Telmisartan Is a non-peptide selective antagonist of AT1R, is often used to treat clinical hypertension and to reduce cardiovascular risk in patients. Telmisartan has shown new pleiotropic actions through induction of PPAR γ activity, providing a

Method

Chemicals and instruments

The materials used in this study are pure Telmisartan powder (Sigma aldrich, USA), ketamine (Hikma, Jordan), Xylazine (RompunTM, 2% vials, Bayer AG, Leverkusen, Germany), ethanol (Fluka, Switzrland) and normal saline (KSA). Mouse tumor necrosis factor- α (TNF- α), interleulin-6 (IL-6), interleukin-1 beta (IL-1 β) enzyme linked immunosorbent assay (ELISA) kits were purchased from Bioscience, Inc. USA. Mous cardiac troponin I ELISA kit was purchased from Life diagnostics Inc., USA. Mouse (Bcl-2) Elisa kit, mouse caspase 3 Elisa kit, was purchased from R&D Systems, Inc. USA. The instruments used in this study were High Intensity Ultrasonic Liquid

Processor (Sonics & materials Inc., USA), Vascular Clamp (Biotechno, Germany) and ventilator (Harvard. USA).

Animals

Thirty adult males Swiss Albino mice weighing 28-33 g were purchased from Animal Resource Center, the National Center for Drug Control and Researches. The animals were apparently healthy and they were housed in the animal house of College of Medicine/University of Kufa in a temperature-controlled ($24 \pm 2^{\circ}\text{C}$) room with ambient humidity and alternating 12-h light/12-h dark cycles and were allowed free access to water and standard chow diet until the start of experiments. The mice were left for two weeks without interference for acclimatization. They had no manifestation of any illness upon examination.

Design of the study

Animals were randomly divided into four groups (six Mice/group) assigned as I, II, III, IV, Group I (sham): Mice were subjected for all surgical procedure without ligation of left anterior descending (LAD) coronary artery. Group II (control): Mice were subjected for entire surgical procedure with ligation of (LAD). Group III (control vehicle): Mice were pretreated with 1% DMSO (vehicle for Telmisartan) then subjected to entire surgical procedure with ligation of (LAD). Group IV (Telmisartan treated group): Mice were treated with 0.5mg/kg [6] via IP injection [7] at 30 minutes before LAD ligation (8) then subjected to entire surgical procedure and ligation.

Surgical procedure and left anterior descending coronary artery (LAD) ligation

Mouse anesthetizes with 100mg/kg ketamine and 5mg/kg xylazine [9]. When the animals became unconscious (within 5-10 min), they were placed in supine position with their limbs fixed with stickers to ensure their immobilization during surgery and head extended with traction suture attached to the upper incisor teeth. Hair in the neck and chest regions was shaved and the skin was sterilized. All operative procedures were carried out in clean conditions. Longitudinal nick incision was made; trachea was reached by removing salivary glands via simultaneously pulling each part sideward with forceps. With the same maneuver, the paratracheal muscles on the midline fascia were split to expose the trachea in the larynx area with stay sutures applied to each side of split strap muscle. The trachea was intubated with a cannula sized either 22 G or 20 G according to the weight of animal with the small catheter reserved for the smaller

animal. Mechanical ventilation was then achieved by connecting the endotracheal tube to scientific ventilator supplied with 100% oxygen at a respiratory rate of 50/min with a tidal volume of 20 mL/kg body weight [10]. Once steady breathing is established, animal's left limbs were fixed with right side limb, left thoracotomy was made between the 3rd and 4th rib and pericardiotomy was performed by using hemostats or round end scissors to open the space, without cutting the tissue so that the risk of bleeding can be reduced. A chest retractor was positioned within the fourth intercostal space in order to spread the ribs so that the left ventricle (LV) is exposed. Maximal care was taken not to damage the lung. A wet piece of small gauze, soaked with normal saline was inserted into the thorax to push back the lungs away and expose the heart .

To have a clear view, the pericardium was removed using electronic microscope and LAD was easily detected. The LAD was transient ligated using a 6-0 prolene suture for a 30-minute ischemic period without exteriorization of the heart [11].

The rate of ventilator gradually was decreases. When spontaneous breathing was sufficient, decision was made for gentle and careful extubation after freeing the rat from tapes. Finally, the rat was transferred into clean cage oxygenated with 100% oxygen and placed near a heating lamp. Cardiac reperfusion was allowed following 120 minutes of the LAD ligation [11].

Microsurgical scissors are used to cut the knot in the ligature. Proper ligation of the LAD was confirmed by observing blanching of myocardial tissue distal to the suture and dysfunction of the anterior wall as observed during the transient LAD ligation. Reperfusion was verified by the return of red color to the myocardial tissue and the demonstration of some recovery of anterior wall motion observed immediately following the transient LAD ligation.

Samples collection

At the end of reperfusion, blood was collected from the ventricles at the apical side. Hearts were cut from their main arteries (aorta and pulmonary artery), rinsed with normal saline to remove any blood, and stored in deep freeze (-20°C) to (-80°C).

The ventricles were cut from the atrio-ventricular junction and divided into two parts, lower (apical) and upper parts. The apical parts of the heart was further divided into two parts, one part used for apoptosis study while the other part was fixed in 10%

formalin and processed by routine histological methods and embedded in paraffin blocks [19]. For subsequent histological examination, 5 μ m-thick horizontal sections were cut and stained with haematoxylin-eosin (H&E).

Samples preparation Preparation of Sample for TNF- α and IL-1 β and IL-6 measurements

The upper parts of the ventricles were washed with cold normal saline to remove any blood, stored in deep freeze (-20°C), and then homogenized with high intensity liquid processor in 1:10 (w/v) phosphate buffered saline that contain 1% triton X-100 and protease inhibitor cocktail [20]. The homogenate was centrifuged with 2,500 g at 4°C for 20 min. The supernatant was collected and used in TNF- α and IL-1 β and IL-6 determination.

Preparation of sample for caspase 3 and Bcl-2 measurment

Rinse cardiac tissues two times with PBS, remove any remained PBS after the second rinse. Solubilize tissue in lysis buffer and allow samples to sit on ice for 15 minutes. Assay stored at \leq -70°C. Before use, centrifuged samples at 2000 x g for 5 minutes and transfer the supernatant to a clean test tube. Sample protein concentration may be quantified using a total protein assay, dilution is made by IC diluent.

Preparation of sample for cTn-I measurement

At the end of reperfusion 0.5 ml blood was collected from the apex of the hearts. Blood samples were placed in a disodium EDTA (22 mg/ml) containing tube, mixed thoroughly and centrifuged at 3000 rpm for 15 min.

Statistical analysis

Statistical analyses were performed using SPSS 20.0 for windows 7 (IBM, USA). Data were expressed as mean \pm SEM unless otherwise stated. One way Analysis of Variance (ANOVA) was used for multiple comparisons among all groups. Pearson correlation coefficient was used to assess the associations between two variables of study parameters. In all test; $P < 0.001$ was considered statistically significant.

Results

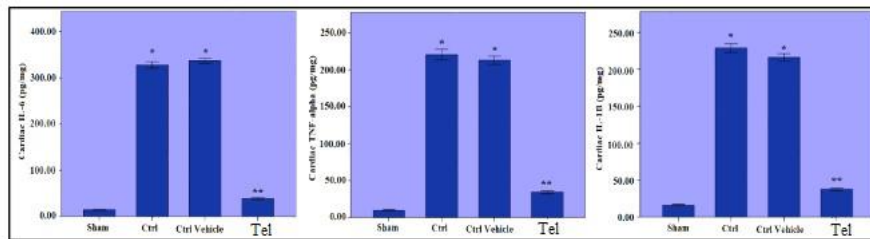
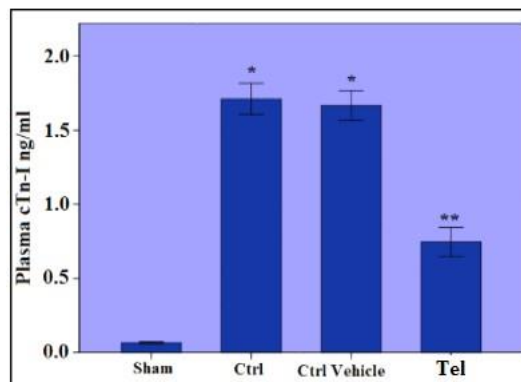


Figure 1.

The levels of cardiac cytokines (TNF- α , IL-1 β and IL-6) were found to be significantly elevated in the control group (II) and control vehicle (III) compared with the sham group (I). At the same time, cardiac cytokines were significantly decreased in Telmisartan treated group (IV) with respect to both control and control vehicle groups. * $P < 0.05$ vs. sham group; ** $P < 0.05$ vs. Ctrl vehicle group.

Figure 2.

The level of plasma increased in control vehicle (III) group (I). On the significantly treated group (IV) control (II) or groups. * $P < 0.05$ vs. vs. Ctrl vehicle group.



cTnI was significantly group (II) and control compared to the sham other hand, cTn-I was reduced in Telmisartan with respect to both control vehicle (III) sham group, ** $P < 0.05$

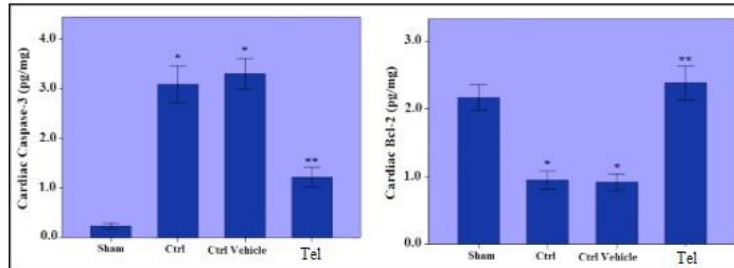


Figure 3.

The levels of cardiac pro apoptotic marker (caspase 3) were found to be significantly elevated in the control group (II) and control vehicle (III) compared with the sham group (I). While anti apoptotic (Bcl-2) were found to be significantly decrease in the control group (II) and control vehicle (III) compared with the sham group (I). At the same time, cardiac caspase 3 were significantly decreased in AT1-AB treated group (IV) with respect to both control and control vehicle groups. While cardiac Bcl-2 significantly elevated in Telmisartan treated group (IV) with respect to both control and control vehicle groups. * $P < 0.05$ vs. sham group, ** $P < 0.05$ vs. Ctrl vehicle group.

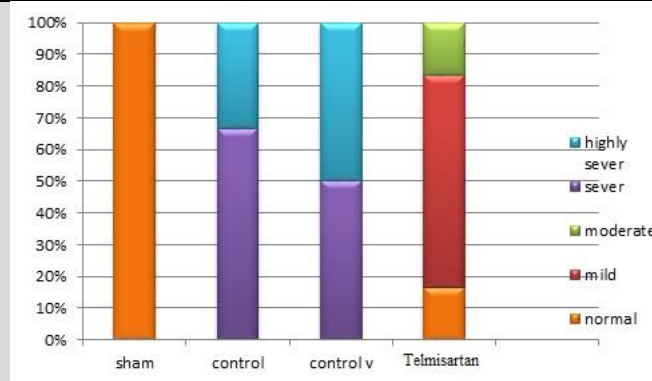


Figure 4.

Component bar chart the relative frequency of different histopathology grading of abnormal heart changes among the four experimental groups. Score 0 (normal), no damage; score 1 (mild), interstitial edema and focal necrosis; score 2 (moderate), diffuse myocardial cell swelling and necrosis; score 3 (severe), necrosis with the presence of contraction bands and neutrophil infiltrate; and score 4 (highly severe), widespread necrosis with the presence of contraction bands, neutrophil infiltrate, and hemorrhage.

Telmisartan reduced myocardial inflammatory response

The levels of myocardial cytokines (TNF- α , IL-1 β and IL-6) were found to be significantly elevated ($P<0.001$) in control group (II) and control vehicle (III) compared with sham group (I). At the same time, cardiac cytokines were significantly decreased ($P<0.001$) in treated Telmisartan group (IV) with respect to both control and control vehicle groups, (Figure 1)

Effect of Telmisartan on the myocardial injury

The level of plasma cTn-I was also significantly increased ($P<0.001$) in control group (II) and control vehicle (III) compared to the sham group (I). On the other hand, cTn-I was significantly reduced ($P<0.001$) in AT1-AB treated group (IV) with respect to both control (II) or control vehicle (III) groups, (Figure 2).

Role of Telmisartan on cardiac Caspase 3, Bcl-2 after myocardial injury

Exposure of myocytes to ischemia/reperfusion injury through LAD ligation significantly increased the pro apoptotic marker (caspase-3) levels ($P<0.001$) in the control group (II) compared to the sham group. Pretreatment with Telmisartan (group IV) significantly reduced ($P<0.001$) caspase-3 levels when compared to the control group (I) and control vehicle group (II), (Figure 5).while the level of cardiac Bcl-2 was significantly decrease ($P<0.001$) in control group (II) and control vehicle (III) compared to the sham group (I). On the other hand, Bcl-2 was significantly increase ($P<0.001$) in Telmisartan treated group (IV) with respect to both control (II) or control vehicle (III) groups, Figure (6).

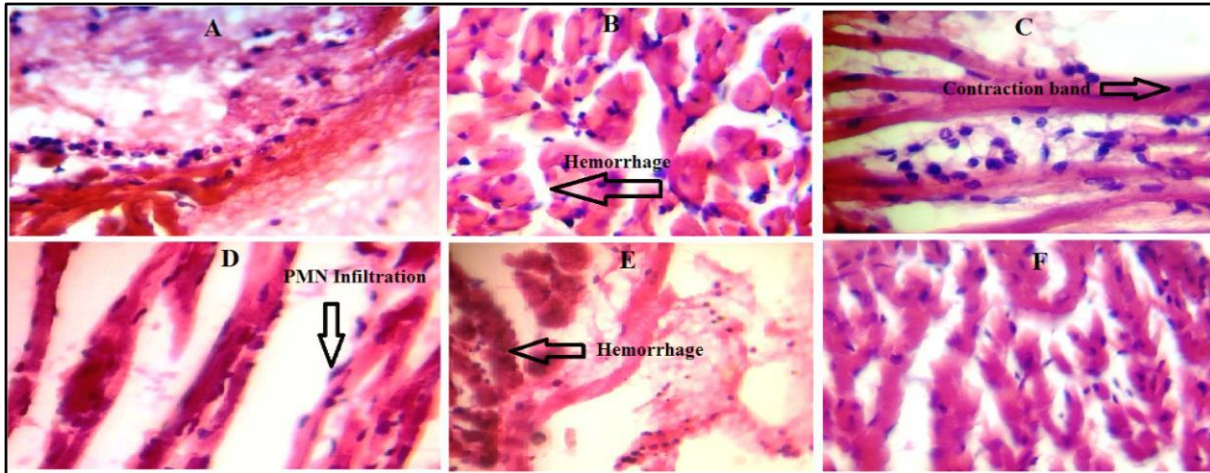


Figure 5.

A representative photomicrograph of a section of the heart tissue section stained with Haematoxylin and Eosin (X 40). A, the sham group shows normal architecture (score 0); no interstitial edema, no diffuse myocardial cell swelling and necrosis, no neutrophils infiltration, no hemorrhage, no capillary compression and no evidence of apoptosis. B, cardiac section for the control group showed hemorrhage, necrosis and neutrophil infiltration. C, cardiac section for the control group showed contraction band and Hemorrhage D, cardiac section for the control vehicle group showed interstitial edema, hemorrhage and PMN infiltration. E, cardiac section of moderate injury showed hemorrhage and PMN infiltration. F, cardiac section after treatment with Telmisartan show almost normal cardiac structure.

Discussion

As show in the results, pretreatment with Telmisartan (group IV) significantly ($P < 0.001$) reduced the inflammatory cytokines (IL-1 β , TNF- α , IL-6), cTn-I and caspase 3 levels when compared to the control group (II) and control vehicle group (III). While there is significantly ($P < 0.001$) increase in level of B cl-2 for Telmisartan treated group when compared with control and control vehicle group.

Reperfusion to the infarcted area is associated with intense inflammatory responses. Inflammatory responses after myocardial I/R injury are detrimental for cell survival and extracellular matrix integrity via enhanced activation of proapoptotic signaling

pathways [14]. Myocardial ischemia has been found to be associated with plasma increased Ang II level [15].

Furthermore, Baichun et al. (1998) [16] showed that a brief period of ischemia followed by reperfusion in isolated rat hearts results in an immediate increase in myocardial AT1 receptor expression and myocardial dysfunction, Apoptosis of cardiomyocytes may further be influenced by Ang II, which binds to the AT1 receptor [17].

Telmisartan is a unique ARB with selective PPAR- γ -modulating activity which affects nitric oxide bioavailability thus leading to its anti-inflammatory, antioxidant and antiproliferative effects on vascular wall cells [18]. Sukumaran et al. (2011b) [19] they found that increased myocardial mRNA expressions of inflammatory cytokines [IL-6, IL-1 β , TNF- α and IF- γ] were suppressed by telmisartan treatment group in experimental autoimmune myocarditis induced in Lewis rats by immunization with porcine cardiac myosin.

Takagi et al (2013) [20] concluded that telmisartan therapy is likely effective in reducing IL-6 and TNF- α levels. Based on a meta-analysis of nine randomized controlled trials. Zeng et al. (2013) [21] found that angiotensin-II concentrations in left ventricular tissue increased subsequent to myocardial I/R. Activation of NADPH oxidase, stimulated by angiotensin-II, generates reactive oxygen species, which in turn may act as signal transduction messengers for NF- κ B. Numerous genes, including interleukin (IL)-1, IL-6, IL-8, interferon- γ , TNF-alpha, ICAM-1 and VCAM-1, are stimulated by activation of NF-Kb [22].

Several studies have suggested that Ang II involved in apoptosis for example, Pollman et al. (1996) [23] showed that Ang II can directly antagonize NO donor- and cGMP analogue-induced apoptosis via activation of AT1R. Li et al. (1999) [24] observed that the effect of Ang II were significantly attenuated by a specific AT1R blocker, indicating and that it is the AT1R activation mediates the pro- apoptotic effects of Ang II.

It has also been reported that telmisartan reduced oxidative stress, apoptosis and improved cardiac function through PPAR γ -mediated effects in diabetic rats with myocardial infarction. Jung et al. (2007) [26] founded that telmisartan attenuated the

activities of caspase-9, caspase-3, and caspase-8, and the mRNA levels of Fas-L and TNF- α , in normotensive rats with intra cerebral hemorrhage.

They speculate that telmisartan can alleviate both the intrinsic and extrinsic apoptotic pathway activation associated with ICH. Sukumaran et al. (2011) [27] investigated the cardioprotective effects of telmisartan against experimental autoimmune myocarditis (EAM) and found that telmisartan treatment significantly decreased the protein expression levels of phospho-p38 mitogen-activated protein kinase (MAPK), phospho-JNK, phospho-ERK and phospho (MAPK) activated protein kinase-2 than with those of vehicle-treated rats. Moreover, telmisartan significantly decreased the production of proinflammatory cytokines, myocardial apoptotic markers and caspase-3 positive cells compared with those of vehicle-treated rats.

Tang et al (2008) [28] found that Telmisartan effectively attenuated the cardiomyocyte apoptosis and cardiac hypertrophy in abdominal aortic banded rats possibly through reducing endoplasm reticulum stress. Grünenfelder et al. (2001) [29] demonstrate that in vivo inhibition of caspase-3 is able to up-regulate Bcl-2 and reduce rat cardiac allograft damage from ischemia/reperfusion injury via restoration of TNF- α levels to concentrations comparable to those in normal hearts.

This myocardial preservation occurs regardless of cytochrome c release and may indicate a greater role for the direct antioxidant effects of Bcl-2. Rinaldi et al (2012) [30] found that the treatment of ZDF rats for 3 weeks with telmisartan, resulted in a significant decrease in the levels of plasma troponin I. In addition the reduction of myocardial damage was induced by I/R and was associated with increased adiponectin and a decrease in inflammatory markers.

Hadi et al (2012) [31] found that telmisartan caused a significant reduction in the level of plasma cardiac troponin I in rat model of doxorubicin induced cardio toxicity. Fogari et al (2012) [32] observed the lesser increase in cTn-I in the telmisartan-treated patients during AF recurrence suggests a greater protective effect of the ARB against the arrhythmia-related myocardial injury.

Treatment of mice with Telmisartan ameliorates heart injury significantly ($P < 0.001$) as compared with induced untreated group. The scores of the control group

showed a severe myocardial injury while the score of Telmisartan treated group showed mild injury.

Iqbal et al (2008) [33] studied the possible protective effect of Telmisartan against doxorubicin induced cardiotoxicity and they found that myocardium of rats pretreated with telmisartan appeared nearly normal. Zeng et al (2013) [21]. Show the muscle fibers of the I/R and GW9662 Groups (PPARG antagonist) had extensive edema, necrosis, and breakage, and a large number of dissolved myocyte nucleoli, Also, the number of PMNs infiltrating the area of the reperfused myocardium was increased in the I/R, In the telmisartan, telmisartan–GW9662, and candesartan groups, the muscle fibers showed less breakage and edema, along with fewer ruptured nucleoli. There was also significantly fewer PMN infiltration in the myocardium of the telmisartan. Furthermore, there were significantly fewer PMNs infiltrating the myocardium in the telmisartan group compared with the telmisartan– GW9662 and candesartan groups.

Competing of interests

The authors declare that there is no conflict of interest.

Author Contributions

All authors wrote, read and approved the final manuscript.

References

1. Singhal AK, Symons JD, Boudina S, Jaishy B, Shiu YE. Role of endothelial cells in myocardial ischemia-reperfusion injury. *Vascular disease prevention* 2010;7:1-14.
2. Deng C, Sun Z, Tong G, Yi W, Ma L, Zhao B, Cheng L, Zhang J, Cao F, Yi D. α Lipoic acid reduces infarct size and preserves cardiac function in rat myocardial ischemia/reperfusion injury through activation of PI3K/Akt/Nrf2 pathway. *PLoS One* 2013; 8(3): e58371.
3. Jugdutt BI. Apoptosis after reperfused myocardial infarction: Role of angiotensin II. *Exp Clin Cardiol* 2014; 9(4):219-228.
4. Yousif NG, Al-amran FG. Novel Toll-like receptor-4 deficiency attenuates trastuzumab (Herceptin) induced cardiac injury in mice. *BMC Cardiovasc Disord* 2011; 11: 62.

5. Takai S, Kirimura K, Jin D, Muramatsu M, Yoshikawa K, Mino Y, Miyazaki M. Significance of angiotensin II receptor blocker lipophilicities and their protective effect against vascular remodeling. *Hypertens Res* 2005; 28(7):593-600.
6. Kaschina E, Schrader F, Sommerfeld M, Kemnitz UR, Grzesiak A, Krikov M, Unger T. Telmisartan prevents aneurysm progression in the rat by inhibiting proteolysis, apoptosis and inflammation. *J Hypertens* 2008; 26(12):2361-73.
7. Amr A. Fouad, Habib A. Qureshi, Ali Ibrahim Al-Sultan, Mohamed T. Yacoubi, Walid N. Al-Melhim. Nephroprotective Effect of Telmisartan in Rats with Ischemia/Reperfusion Renal Injury. *Pharmacology* 2010; 85:158-167.
8. Kumtepe Y, Odabasoglu F, Karaca M, Polat B, Halici MB, Keles ON, Altunkaynak Z, Gocer F. Protective effects of telmisartan on ischemia/reperfusion injury of rat ovary: biochemical and histopathologic evaluation. *Fertil Steril* 2010; 193(4):1299-307.
9. Wiedemann D, Schneeberger S, Friedl P, Zacharowski K, Wick N, Boesch F, Margreiter R, Laufer G, Petzelbauer P, Semsroth S. The fibrin-derived peptide Bbeta(15-42) significantly attenuates ischemia-reperfusion injury in a cardiac transplant model. *Transplantation* 2010; 15;89(7):824-9.
10. Ding JW, Tong XH, Yang J, Liu ZQ, Zhang Y, Yang J, Li S, Li L. Activated protein C protects myocardium via activation of anti-apoptotic pathways of survival in ischemia-reperfused rat heart. *J Korean Med Sci* 2010; 25:1609-15.
11. Maekawa N, Wada H, Kanda T, Niwa T, Yamada Y, Saito K, Fujiwara H, Sekikawa K, Seishima M. Improved myocardial ischemia/reperfusion injury in mice lacking tumor necrosis factor- α . *J Am Coll Cardiol* 2010; 3;39(7):1229-35.
12. Bancroft JD, Stevens A. *Theory and practice of histological techniques*. Churchill Livingstone. Melbourne 1982; 2:125.
13. Zhang M, Xu YJ, Saini HK, Turan B, Liu PP, Dhalla NS. Pentoxifylline attenuate cardiac dysfunction and reduces TNF α level in ischemia-reperfused heart. *Am J Physiol Heart Circ Physiol* 2005; 289: 832-9.
14. Arslan F, Smeets MB, O'Neill LA, Keogh B, McGuirk P, Timmers L, Tersteeg C, Hofer IE, Doevendans PA, Pasterkamp G, de Kleijn DP. Myocardial ischemia/reperfusion injury is mediated by leukocytic toll-like receptor-2 and reduced by systemic administration of a novel anti-toll-like receptor-2 antibody. *Circulation* 2010; 5;121(1):80-90.
15. Deng H, Guo H, Qian X. Clinical significance of fibrinolytic system defectiveness in exercise induced myocardial ischemia and its mechanism. *Chung Hua Nei Ko Tsa Chih* 1995; 34: 305-308.

16. Yang B, Li D, Phillips M, Mehta P, Mehta JL. Myocardial angiotensin II receptor expression and ischemia-reperfusion injury. *Vasc Med* 1998;3:21–130.
17. Leri A, Claudio PP, Li Q, Wang X, Reiss K, Wang S, Malhotra A, Kajstura J, Anversa P. Stretch-mediated release of angiotensin II induces myocyte apoptosis by activating p53 that enhances the local renin-angiotensin system and decreases the bcl2-to Bax protein ratio in the cell. *J Clin Invest* 1998;101: 1326–1342.
18. Yamagishi S, Takeuchi M. Telmisartan is a promising cardiometabolic sartan due to its unique PPAR-gamma-inducing property. *Med Hypotheses* 2005; 64:476–478.
19. Sukumaran V, Watanabe K, Veeraveedu PT, Ma M, Gurusamy N, Rajavel V, Suzuki K, Yamaguchi K, Kodama M, Aizawa Y. Telmisartan ameliorates experimental autoimmune myocarditis associated with inhibition of inflammation and oxidative stress. *Eur J Pharmacol* 2011;10;652(1-3):126-35.
20. Takagi H, Mizuno Y, Yamamoto H, Goto SN, Umemoto T. Effects of telmisartan therapy on interleukin-6 and tumor necrosis factor-alpha levels: a meta-analysis of randomized controlled trials. *Hypertens Res* 2013; 36(4):368-73.
21. Zeng XC, Li XS, Wen H. (2013) Telmisartan protects against microvascular dysfunction during myocardial ischemia/reperfusion injury by activation of peroxisome proliferator-activated receptor gamma. *BMC Cardiovasc Disord* 2013;5;13(1):39.
22. Muller DN, Dechend R, Mervaala EM, Park JK, Schmidt F, Fiebeler A, Theuer J, Breu V, Ganten D, Haller H. NF-kappaB inhibition ameliorates angiotensin II-induced inflammatory damage in rats. *Hypertension* 2000;35(1 Pt 2):193-201.
23. Pollman MJ, Yamada T, Horiuchi M, Gibbons GH. Vasoactive substances regulate vascular smooth muscle cell apoptosis: countervailing influences of nitric oxide and angiotensin II. *Circ Res* 1996;9:748–756.
24. Li D, Tomson K, Yang B, Mehta P, Croker BP, Mehta JL. Modulation of constitutive nitric oxide synthase, bcl-2 and Fas expression in cultured human coronary endothelial cells exposed to anoxia/reoxygenation and angiotensin II: role of AT1 receptor activation. *Cardiovasc Res* 1999; 41(1):109-15.
25. Goyal S, Arora S, Bhatt TK, Das P, Sharma A, Kumari S, Arya DS. Modulation of PPAR-gamma by telmisartan protects the heart against myocardial infarction in experimental diabetes. *Chem Biol Interact* 2010; 185(3):271–280.
26. Jung KH, Chu K, Lee ST, Kim SJ, Song EC, Kim EH, Park DK, Sinn DI, Kim JM, Kim M, Roh JK. Blockade of AT1 receptor reduces apoptosis, inflammation, and oxidative stress in normotensive rats with intracerebral hemorrhage. *J Pharmacol Exp Ther* 2007; 322(3):1051-8.

27. Sukumaran V, Veeraveedu PT, Gurusamy N, Yamaguchi K, Lakshmanan AP, Ma M, Suzuki K, Kodama M, Watanabe K. Cardioprotective effects of telmisartan against heart failure in rats induced by experimental autoimmune myocarditis through the modulation of angiotensin-converting enzyme-2/angiotensin 1-7/mas receptor axis. *Int J Biol Sci* 2011; 7(8):1077-92.
28. Tang JR, Yan XN, Zhou CQ. Effects of telmisartan on endoplasmic reticulum stress induced cardiomyocyte apoptosis in abdominal aortic banded rats. *Zhonghua Xin Xue Guan Bing Za Zhi*. 2008; 36(9):838-42.
29. Grünenfelder J, Miniati DN, Murata S, Falk V, Hoyt EG, Kown M, Koransky ML, Robbins RC. Upregulation of Bcl-2 through caspase-3 inhibition ameliorates ischemia/reperfusion injury in rat cardiac allografts. *Circulation* 2001;18;104(12 Suppl 1): I202-6.
30. Rinaldi B, Di Filippo C, Capuano A, Donniacuo M, Sodano L, Ferraraccio F, Rossi F, D'Amico M. Adiponectin elevation by telmisartan ameliorates ischaemic myocardium in Zucker diabetic fatty rats with metabolic syndrome. *Diabetes Obes Metab* 2012;14(4):320-8.
31. Austin EW, Yousif NG, Ao L, Fullerton DA, Meng X. Ghrelin reduces myocardial injury following global ischemia and reperfusion via suppression of myocardial inflammatory response. *American journal of BioMedicine* 2013;1(2):33-47.
32. Fogari R, Mugellini A, Zoppi A, Preti P, Destro M, Lazzari P, Derosa G. Effect of telmisartan and ramipril on atrial fibrillation recurrence and severity in hypertensive patients with metabolic syndrome and recurrent symptomatic paroxysmal and persistent atrial fibrillation. *J Cardiovasc Pharmacol Ther* 2012; 17(1):34-43.
33. Iqbal M, Dubey K, Anwer T, Ashish A, Pillai KK. Protective effects of telmisartan against acute doxorubicin-induced cardiotoxicity in rats. *Pharmacol Rep* 2008;60(3):382-90
34. Yousif NG, Ao L, Li J, Aly A, Austin E, Fullerton DA, Meng X. Myocardial tissue TLR4 plays a major role in mediating myocardial injury following cold ischemia and reperfusion through up-regulation of MCP-1. *Journal of Surgical Research* 2011; 165(2):181.