

Grade II limbal dermoid excision and lamellar graft in 11 months old baby

Zaid Yousif Hameed Shukur ¹**Abstract**

Epibulbar dermoids are the most common episcleral choristomas, these lesions may present unilaterally or bilaterally, and the majority (85%) are located in regions of the bulbar conjunctiva, limbus, cornea, and/or caruncles. An 11 months old male baby presented to my office by his parents, they were worry about a mass in his right eye. I examined the baby started to inspect his eyes by a torch then by the slit lamp biomicroscope and it revealed large elevated white pale mass with overlying hairs and slight yellow tinge on the surface of the mass, clinically it is a limbal dermoid on the inferotemporal aspect of the right globe. Congenital limbal dermoid in this case was according to surgical size and depth is regarded as grade II limbal dermoid, which in such case need for surgical excision because it cause high degree of astigmatism, the other indications include the effect on the visual axis, the dellen formation in adjacent corneal surface and also surgical indication for cosmetic purpose. In this case it caused high astigmatism with amblyopia in addition to the cosmetic effect on the patient's eye.

Keywords: Limbal dermoid; Dellen formation; Slit lamp; Anisometropic amblyopia

*Corresponding Author: Zaid Yousif Hameed Shukur: zaidshukur2013@yahoo.com

¹Department of physiology, College of Medicine, Kufa University

Received 09 January 2015; accepted 05 March 2015; published 29 March 2015

Copyright © 2014 ZH. *et al.* This is article distributed under the terms of the Creative Commons Attribution License (<http://creativecommons.org/licenses/by/2.0>), which permits unrestricted use, distribution, and reproduction in any medium, provided the original work is properly cited.

Introduction

Epibulbar dermoids are the most common episcleral choristomas, i.e. congenital overgrowth of normal tissues by collagenous connective tissue covered by epidermoid epithelium in an abnormal location, and involving the globe in children. These lesions may present unilaterally or bilaterally, and the majority (.85%) are located in regions of the bulbar conjunctiva, limbus, cornea, and/or caruncles [1].

Histopathology, incidence, and pathogenesis

Epibulbar dermoids may present as a single lesion or as multiple lesions. They are marginally vascularized, smooth, whitish lesions with sebaceous components generally located in the inferotemporal globe or temporal limbus [2–5]. Epibulbar choristomas are thought to arise from an early embryological anomaly (occurring at 5–10 weeks' gestation) resulting in metaplastic transformation of the mesoblast between the rim of the optic nerve and surface ectoderm [6].

Anatomically, epibulbar dermoids have been classified into three grades [7]. This form of grading allows clinicians to take a more stepwise approach to the clinical and surgical management of such lesions. Grade I limbal dermoids are superficial lesions measuring less than 5 mm and are localized to the limbus. Such lesions may lead to development of anisometropic amblyopia, with slow growth resulting in oblique astigmatism and flattening of the cornea adjacent to the lesion.

Grade II limbal dermoids are larger lesions covering most of the cornea and extending deep into the stroma down to Descemet's membrane without involving it. Grade III limbal dermoids, the least common of all the presenting dermoids, are large lesions covering the whole cornea and extending through the histological structures between the anterior surface of the eyeball and the pigmented epithelium of the iris [8].

Genetics and inheritance

The pattern of inheritance is quite variable in epibulbar choristomas. They can be autosomal dominant, recessive, X-linked, or multifactorial [2].

Medical management

Medical management is generally reserved for grade I dermoids which always are smaller lesions in terms of diameter and height, inducing only mild astigmatism of 1 D or less, with minimal surface irregularity, and parents mention relatively good compliance with spectacle correction. The main recommendation noted in the literature is to "leave these lesions alone" [9, 10] and one would tend to agree. Essentially small asymptomatic grade I limbal dermoids should not be removed because they may lead to postoperative scarring and development of pseudopterygium. It is recommended that these children undergo close clinical observation with serial examinations in the office, not only to monitor stability but also to provide reassurance for parents [8].

During each office examination, which should be performed once every 8-12 weeks, visual acuity and presence or absence of amblyopia must be established and advice should be given on occlusion therapy. The size of the lesion, ideally captured and measured by photography, visual acuity, stereo acuity, cycloplegic refraction, and gonioscopy, need to be addressed, whenever possible. These serial examinations should continue in all cases unless patients meet the following criteria for surgical intervention: development of clinically significant anisometropia; presence of amblyopia is impending or established; lack of compliance with either follow-up or spectacle correction is recognized; growth of limbal dermoid induces marginal dellen, resulting in surface disease and increasing anisometropic astigmatism; and esthetic considerations.

When any of the above conditions or combination of conditions is noted, surgery should be considered and thoroughly discussed with the parents, including the potential risk of scarring, the requirement for ongoing treatment of amblyopia after surgery, need for spectacle or contact lens wear, possible repeat surgery, and loss of vision.

Indications for surgery

There are recognized clinical indications for proceeding with surgical excision and anterior surface reconstruction in patients with a grade I limbal dermoid. For example, if a child or the parents are not compliant with wearing of corrective spectacles, even for mild astigmatism, one may consider surgical excision in the presence of amblyopia.

However, if adherence with spectacle wear is good in the setting of large, regular, and oblique astigmatism, and adequate follow-up for clinical treatment of amblyopia is possible, surgeons may opt to defer surgical intervention. In the presence of amblyopia, one must exhaust all efforts to treat amblyopia medically, including with spectacles and occlusion therapy. Conversely, if the astigmatism is irregular or if the patient is not compliant with wearing of spectacles, surgical excision and reconstructive steps are indicated. Surgery is universally indicated for grade II and III limbal dermoids, given that they generally cause refractive or occlusive amblyopia [8].

Surgical management

A variety of surgical techniques has been described in the literature, ranging from simple excision to lamellar and/or penetrating keratoplasty with relaxing corneal incision, depending on the grade of the lesion. Depth, size, and site of such lesions are

critical factors. Other techniques include corneal-limbal scleral donor graft transplantation and surgical resection followed by reconstructive sutureless multilayered amniotic membrane transplantation [11-13].

In a retrospective review of 50 patients with ocular dermoids identified in the literature from 1970 to 1985, Nevares et al. reported that, in children aged 2–19 months, 68% comprised epibulbar dermoids, and advocate excision of these lesions with simple superficial keratectomy [4]. These authors also cautioned that the graft may opacify over time and a second surgical graft may be necessary. No other complications were noted, but visual acuity and long-term results were not reported.

Burillon et al. [5] reviewed the records of 12 patients with solid ocular tumors between 1985 and 1993, reporting that six lesions could be easily shaved off the cornea and adjacent sclera to improve the appearance of the eye. Visual acuity remained unchanged. In another three cases, they reported that a degree of refractive amblyopia persisted after late surgery, and visual acuity continued to be less than 20/200. In another two cases, early corneolamellar keratoplasty for large limbal dermoids improved best-corrected visual acuity (BCVA). They also suggested that early surgery with simple local resection (combined with a conjunctival flap in order to cover the exposed area) may be preferred to lamellar keratoplasty.

In a retrospective review of 17 patients with limbal dermoids, Robb et al [9] found that 13(76%) had astigmatism of 1.0 D or greater in the involved eye. In all but one patient, the minus cylinder axis of the astigmatism coincided with the location of the dermoid. Thirteen patients underwent simple surgical excision to remove their dermoid at ages ranging from 8 months to 15 years. The astigmatism persisted postoperatively, with little change in orientation or amount, regardless of patient age at the time of surgery. No complications were reported in this study.

In 1961, Bourne treated a series of four pediatric patients with grade II limbal dermoid by direct excision followed by lamellar keratoplasty using a 5–7 mm trephine with a good outcome [10]. He reported no herniation of tissues posterior to the repaired site and no graft failures, but did not provide any details on visual acuity. Although the results of surface reconstruction was satisfactory, it is possible that the final visual acuity was limited because of the older age of the patients and lack of follow-up treatment for amblyopia in some cases.

Zaidman et al reported on two-stage excision of a protuberant congenital corneal dermoid that extended into the anterior chamber in an infant aged one month [11].

A 12 mm lamellar keratectomy was followed 3 months later by a smaller (8 mm) penetrating keratoplasty. These authors considered that this technique minimized the complications associated with large corneal transplants and increased the chance of long-term success. The graft remained transparent without complication or rejection, and the infant continued to maintain constant fixation initially.

Panton and Sugar reviewed the clinical files of 10 patients who had undergone simple excision of a unilateral grade I epibulbar limbal dermoid. Preoperatively, all of the affected eyes had significantly worse visual acuity ($P= 0.02$) and more astigmatism ($P= 0.01$) than the contralateral eyes. Postoperatively, every patient showed cosmetic improvement. Of the eight patients for whom both preoperative and postoperative visual acuity measurements had been obtained, six showed minimal change (#one line) and two showed improvement (#two lines). Surgical complications included persistent epithelial defects (40%) and peripheral corneal vascularization and opacity (70%) [12]. Kaufman et al have also discussed in detail their selective surgical approach to the treatment of various corneal limbal dermoids in children [13-17].

Scott et al reported that seven of their 11 patients had a single inferotemporal limbal dermoid, with one patient having two dermoids in one eye. Their median follow-up time was 21.6 months, and eight of the 11 patients showed good or excellent cosmetic results with minimal interface haze and no vascularization. Vascularization developed postoperatively in two cases with previously excised lesions. One of these cases developed graft infection, underwent subsequent debridement, and had an opaque graft. BCVA was maintained or slightly improved in nine of these patients. For the group overall and most individual patients, mean astigmatism, spherical equivalent, and refraction, as assessed by surgically-induced refractive change and h-vector analysis, were not significantly changed [17-23].

Patient selection and preoperative evaluation

Despite their benign nature, grade I epibulbar/limbal dermoids may affect vision by gradually inducing corneal astigmatism, leading to profound anisometropic amblyopia, which is mostly reversible in the early years [9]. Conservative management by observation may not be a suitable option for such lesions. Enlarging perilimbal dermoids may also cause disturbance of the ocular surface tear film, forming dellens which result in surface irritation, discomfort, and rubbing of the eye [9]. There is debate

among pediatric and corneal surgeons about the appropriate timing of excision and the optimal method for surgical repair of the corneal defect following resection [11-13].

The optimal timing of surgical excision appears to depend on multiple factors, including the original size of the lesion, its rate of growth, and the anatomical area involved, as well as request for removal for psychosocial reasons [11–13]. Overriding clinical indications for surgery include tumor size and growth, secondary corneal defect, unresponsive amblyopia, and psychosocial and cosmetic considerations.

A thorough history should be taken from the parents, and serial in-office examinations with cycloplegic retinoscopy must be performed to monitor the size of the corneal dermoid. Presence or lack of amblyopia must be established. If in-office examinations or serial evaluations are not feasible, clinical examination should be done under general anesthesia along with an anterior segment high resolution B-scan (ultrasound biomicroscopy) to assess for involvement of Descemet's membrane. These steps are necessary in order to plan for the appropriate surgical approach [14–16].

Hoops et al advocate meticulous biomicroscopic ultrasound examination to improve the depth of corneal penetration for sound waves. Their study shows that dermoids produce strong sound attenuation, reducing the visibility of deep corneal structures and in particular Descemet's membrane [15].

Future management of limbal dermoids

Although in depth management of grade III limbal dermoids have been described in the literature, the surgical management of grade I and II limbal dermoids continues to evolve as a result of developing technology. Adjunctive therapeutic modalities with variously shaped femtosecond laser-assisted anterior lamellar keratoplasty versus Intralase-enhanced penetrating keratoplasty, deep anterior lamellar keratoplasty or topical application of a low-dose antimetabolite (i.e, mitomycin C) after obtaining anterior segment optical coherence tomography with subsequent reconstruction are just some examples of where future clinical trials may take us in the near future in terms of the best surgical outcome following surgical excision of corneal or perilimbal dermoids.

A combination of surgical approaches involving excision of the dermoid from the sclera and partial keratectomy followed by reconstructive steps using a pericardial patch graft on the sclera with overlying conjunctival autologous limbal stem cell transplantation and volumetric filling of the residual corneal defect with fresh

multilayered amniotic membrane rather than lamellar keratoplasty (deep or superficial) may allow for the best functional, refractive, and cosmetic outcomes postoperatively.

Method

An 11 months old male baby presented to my office by his parents, they were worry about a mass in his right eye. I examined the baby started to inspect his eyes by a torch then by the slit lamp biomicroscope and it revealed large elevated white pale mass with overlying hairs and slight yellow tinge on the surface of the mass, clinically it is a limbal dermoid on the inferotemporal aspect of the right globe. I advise the parents to do visual acuity testing to observe the effect of dermoid on its visual acuity, and it revealed 6/24 on his right eye and 6/9 on his left eye.

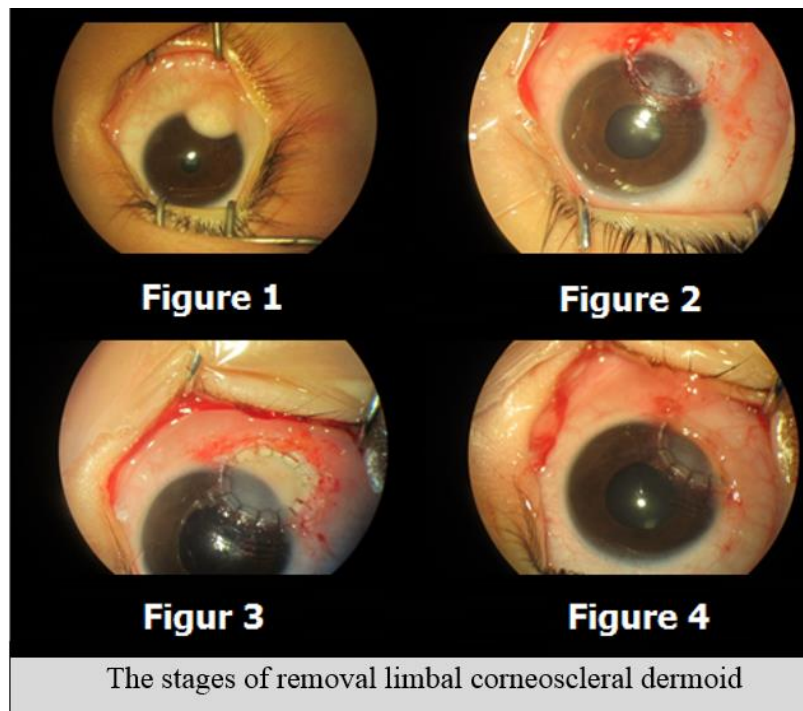
I discussed the situation with the parents to do examination under general anesthesia. The examination revealed a limbal corneoscleral dermoid elevated, white pale colored with a yellow tinge on its top, with overlying hair follicles. Soft rubbery in consistency, measuring 5 mm width by 6.5 mm in its long axis situated at the inferotemporal quadrant of the right limbus (Fig.1). Anterior chamber was clear with globe inversion no anterior chamber involvement by the dermoid and it looks only involve about three quarters of the corneal stromal thickness. Clinically it is classified as grade II limbal dermoid. The iris was normal and the crystalline lens was clear. Refraction was +1/-5.5 DC axis 45°.

Fundus examination revealed normal blood vessels, normal peripheral retina, pink sharp margin optic disc, the intraocular pressure was 14.5, the WTW horizontal diameter was 10.2mm vertical and 10.9mm horizontal diameter, my plane was to do surgery to excise this dermoid. I did conjunctival peritomy starting from the most peripheral parts of the dermoid from the scleral side. Then started to excise by gentle dissection from scleral side towards the limbus, then I chose 7 mm diameter trephine to enclose the whole width of the dermoid and to leave a margin of a healthy corneal tissue in place. Then I started to do dissection from the most central part of the corneal side of the dermoid by the crescent knife toward the limbus I did gentle deepening of the dissection till I reached clear corneal bed (Fig. 2). Then I put 7.5 mm lamellar graft 350 Um thickness and sutured the lenticule with 16 interrupted 10/0 nylon sutures (Fig. 3). Then I burred all the sutures and then returned back the conjunctiva over the exposed

part of the sclera (Fig. 4). I injected sub conjunctival dexamethasone 4mg and gentamycin 20 mg subconjunctivally and packed the eye.

• Chronic eye rubbing due to irritation and recurrent conjunctivitis
• Amblyopia unresponsive to medical management
• Progressive dellen, with corneal surface decompensation
• Growth and encroaching into pupillary area or optical zone
• Esthetic considerations
• Induction of irregular astigmatism
• Inadequate lid closure
Table 1. Indications for primary surgical intervention in grade I limbal dermoids

Recommended techniques	Grade of pediatric limbal/corneal dermoid
Simple excision	Grade I: ,50 µm thickness and ,1 mm diameter
Keratotomy + AMT + ALSCA	Grade I: , 100 µm thickness and ,1 mm diameter
Keratotomy + AMT + LSCA + PPG versus anterior or deep anterior lamellar keratoplasty ± AMT	Grade II and deeper Grade I
Total anterior segment reconstruction	Grade III
Abbreviations: AMT, amniotic membrane transplantation (multilayered); ALSCA, autologous limbal stem cell allograft; PPG, pericardial patch graft [8].	
Table 2. Guarded recommendations for surgical removal of ocular dermoids.	



Discussion

Congenital limbal dermoid in this case was according to surgical size and depth is regarded as grade II limbal dermoid, which in such case need for surgical excision because it cause high degree of astigmatism, the other indications include the effect on the visual axis, the dellen formation in adjacent corneal surface and also surgical indication for cosmetic purpose. In this case it caused high astigmatism with amblyopia in addition to the cosmetic effect on the patient's eye.

Competing interests

The authors declare that there is no conflict of interest.

References

1. American Academy of Ophthalmology. Basic and Clinical Science Course. 2012. Series 6. American Academy of Ophthalmology.
2. Mansour AM, Barber JC, Reinecke RD, Wang FM. Ocular choristomas. *Surv Ophthalmol* 1989; **33**:339-358.

3. Mohan M, Mukherjee G, Panda A. Clinical evaluation and surgical intervention of limbal dermoid. *Indian J Ophthalmol* 1981; **29**: 69-73.
4. Nevares RL, Mulliken JB, Robb RM. Ocular dermoids. *Plast Reconstr Surg* 1988; **82**:959-964.
5. Burillon C, Duran L. Solid dermoids of the limbus and the cornea. *Ophthalmologica* 1997; **211**:367-372.
6. Mann I. Developmental Abnormalities of the Eye. Cambridge, UK: Cambridge University Press; 1937.
7. Mann I. Developmental Abnormalities of the Eye. In: Mann I, 2nd ed. Philadelphia, PA: Lippincott; 1957.
8. Amir Pirouzian Clinical Ophthalmology. Pirouzian, publisher and licensee Dove Medical Press Ltd, 2003.
9. Robb RM. Astigmatic refractive errors associated with limbal dermoids. *J Pediatr Ophthalmol Strabismus* 1996; **33**:241-243.
10. Bourne RA. Epibulbar dermoid tumours of the corneal limbus treated by lamellar keratoplasty. *Trans Can Ophthalmol Soc* 1961; **24**:153-158.
11. Zaidman GW, Johnson B, Brown SI. Corneal transplantation in an infant with corneal dermoid. *Am J Ophthalmol* 1982; **93**:78-83.
12. Panton RW, Sugar J. Excision of limbal dermoids. *Ophthalmic Surg* 1991; **22**:85-89.
13. Kaufman A, Medow N, Phillips R, Zaidman GJ. Treatment of epibulbar limbal dermoids. *J Pediatr Ophthalmol Strabismus* 1999; **36**:136-140.
14. Lanzl IM, Augsburger JJ, Hertle RW, Rapauano C, Corea-Melling Z, Santa Cruz C. The role of ultrasound biomicroscopy in surgical planning for limbal dermoids. *Cornea* 1998; **17**:604-606.
15. Hoops JP, Ludwig K, Boergen KP, Kampik A. Preoperative evaluation of limbal dermoids using high-resolution biomicroscopy. *Graefes Arch Clin Exp Ophthalmol* 2001; **239**:459-461.
16. Grant CA, Azar D. Ultrasound biomicroscopy in the diagnosis and management of limbal dermoid. *Am J Ophthalmol* 1999; **128**:365-367.
17. Scott JA, Tan DT. Therapeutic lamellar keratoplasty for limbal dermoids. *Ophthalmology* 2001; **108**:1858-1867.
18. Shen YD, Chen WL, Wang IJ, Hou YC, Hu FR. Full-thickness central corneal grafts in lamellar keratoscleroplasty to treat limbal dermoids. *Ophthalmology* 2005; **112**:1955.
19. Watts P, Michaeli-Cohen A, Abdolell M, Rootman D. Outcome of lamellar keratoplasty for limbal dermoids in children. *J AAPOS* 2002; **6**:209-215.

20. Panda A, Ghose S, Khokhar S, Das HJ. Surgical outcomes of epibulbar dermoids. *J Pediatr Ophthalmol Strabismus* 2002; **39**:20-25.
21. Mader TH, Stulting D. Technique for the removal of limbal dermoids. *Cornea* 1998; **17**:66-67.
22. Pirouzian A, Holz H, Merrill K, Sudesh R, Karlen K. Surgical management of pediatric limbal dermoids with sutureless amniotic membrane transplantation and augmentation. *J Pediatr Ophthalmol Strabismus* 2012; **49**:114-119.
23. Pirouzian A, Ly H, Holz H, Sudesh RS, Chuck RS. Fibrin-glue assisted multilayered amniotic membrane transplantation in surgical management of pediatric corneal limbal dermoid: a novel approach. *Graefes Arch Clin Exp Ophthalmol* 2011; **249**:261-265.