



**Irbesartan ameliorate inflammatory responses, and apoptosis induced by myocardial ischemia/reperfusion in male rats**

Najah R. Hadi <sup>1</sup>, Fadhil G. Al-Amran <sup>2</sup>, Maitham G Yousif <sup>3</sup>, Suhaad T. Zamil <sup>1</sup>

**Abstract**

Myocardial ischemia–reperfusion (I-R) represents a clinically relevant problem associated with thrombolysis, angioplasty and coronary bypass surgery. This study was undertaken to investigate the potential role of Irbesartan in amelioration of myocardial I/R injury induced by ligation of coronary artery (LAD) in a rat model. We are pretreated the animals with Irbesartan 3mg/kg i.p. 30 minutes before ligation of LAD. At the end of experiment (2 h of reperfusion), blood samples were collected from the heart for measurement of plasma level of cardiac troponin I (cTn-I). Compared with the sham group, levels of myocardial TNF- $\alpha$ , IL-1 $\beta$ , IL-6, MCP-1, MIP-1alpha, and plasma cTn-I were increased ( $P<0.05$ ). Histologically, all rats in control group showed significant cardiac injury. Furthermore, rats in control group showed significant apoptosis. Irbesartan significantly counteract the increase in myocardium level of TNF- $\alpha$ , IL-1B, IL-6, MCP-1, MIP-1alpha, plasma cTnI and apoptotosis ( $P<0.05$ ). Histological analysis revealed that Irbesartan markedly reduced the severity of heart injury in the rats underwent LAD ligation procedure. We concluded that Irbesartan may ameliorate myocardial I/R injury in rats via interfering with inflammatory reactions and apoptosis which induced by I/R injury.

**Keywords:** Ischemia-Reperfusion; LAD; Irbesartan; Cytokines; Apoptosis

Corresponding Author: Najah Hadi:


1 Department of Pharmacology and Therapeutics College of Medicine, Kufa University, Iraq

2 Department of cardiovascular surgery College of Medicine, Kufa University

3 College of science, Al-qadesiyah University

Received January 09, 2019; Accepted May 23, 2019; Published June 22, 2019

Copyright © 2019 NH., et al. This is article distributed under the terms of the Creative Commons Attribution License (<http://creativecommons.org>), which permits unrestricted use, distribution, and reproduction in any medium, provided the original work is properly cited.



**Introduction**

Ischemia/reperfusion injury describes the experimentally and clinically prevalent finding that tissue ischemia with inadequate oxygen followed by successful reperfusion initiates a wide and complex array of inflammatory responses that may aggravate local injury as well as induce impairment of remote organ function [1]. Ischemia-reperfusion injury results from several interdependent mechanisms, namely oxidative stress, intracellular calcium overload and hyper contracture, endothelial cell activation with micro vascular dysfunction and altered myocardial metabolism [2].

Ischemia–reperfusion injury prompts a release of oxygen free radicals, cytokines and other pro inflammatory mediators that activate both the neutrophils and the coronary vascular endothelium. Activation of these cell types promotes the expression of adhesion molecules on both the neutrophils

and endothelium, which recruits neutrophils to the surface of the endothelium and initiates a specific cascade of cell– cell interactions, leading first to adherence of neutrophils to the vascular endothelium, followed later by transendothelial migration and direct interaction with myocytes. This specific series of events is a prerequisite to the phenotypic expression of reperfusion injury, including endothelial dysfunction, micro vascular collapse and blood flow defects, myocardial infarction and apoptosis [3].

I–R injury may occur in a variety of clinical settings, including reperfusion after thrombolytic therapy, coronary angioplasty, organ transplantation, aortic crossclamping or cardiopulmonary bypass [4]. Adaptive cellular responses activate the innate immune system with its Toll-like receptors and the complement system as well as the adaptive immune system. This results in a profound inflammatory tissue reaction with immune cells infiltrating the tissue. The damage is mediated by various cytokines, chemokines, adhesion molecules, and compounds of the extracellular matrix. The expression of these factors is regulated by specific transcription factor with NF- $\kappa$ B being one of the key modulators of inflammation [5].

Apoptosis is another mechanism of myocardial injury associated with ischemia– reperfusion injury, it seems that apoptotic cell death in the myocardium is initiated during ischemia, but the energy needed for the execution is provided during reperfusion [6]. Cells undergoing apoptosis exhibit several typical features including shrinkage, cell membrane disruption, cytoskeletal rearrangement, nuclear condensation, and inter nucleosomal DNA fragmentation [7]. The degradation of DNA into fragments approximately 185 bp with its multiples in size is one of the best characterized biochemical features of apoptotic cell death which is used as the basis for the commonly used labeling techniques for detecting apoptotic cells [8].

Ang II is a key activator of reactive oxygen species(ROS) formation and oxidative stress in the cardiovascular system with the NADPH oxidase being a principal player. Interestingly, AT1 blockade completely suppressed this increased NADPH oxidase activity in these mice consistent with the notion that Ang II-mediated activation of NADPH oxidase occurs via the AT1 receptors [9]. AngII-induced apoptosis can be blocked in post-infarcted, hypertrophied ventricular myocytes by AT1 blockers, but AT2 antagonists had no impact on these cellular events [10].

Irbesartan is selectively binds to the ANG-II receptor subtype 1, thereby inhibiting the activity of ANG-II. Irbesartan significantly ameliorated left ventricular ischemia and prevented the development of cardiac hypertrophy and fibrosis in Salt-loaded Dahl salt-sensitive hypertensive rats (DS rats). The benefits were associated with the attenuation of oxidative stress, normalization of myocardial capillary density and inhibition of capillary endothelial apoptosis [11].

## Method and materials

### Animals

A forty adult males Swiss Albino rat weighing 180-220 g were purchased from Animal Resource Center, the National Center for Drug Control and Researches. The animals were apparently healthy and they were housed in the animal house of College of Medicine/University of Kufa in a temperature-controlled ( $24 \pm 2$  °C) room with ambient humidity and alternating 12-h light/12-h dark cycles and were allowed free access to water and standard chow diet until the start of experiments. The rat was left for two weeks without interference for acclimatization. They had no manifestation of any illness upon examination.

### In vivo myocardial I/R model

The *in vivo* myocardial I/R model was modified from a previous study [12]. Briefly, rats were anesthetized with 100mg/kg ketamine and 5mg/kg xylazine [13]. The rats were intubated and Mechanical ventilation is then achieved by connecting the endotracheal tube to scientific ventilator (Harvard Model) at a respiratory rate 138 breath/minute with a tidal volume of 20 mL/kg body weight [14]. A left thoracotomy was carried out to expose the heart. The LAD is then transiently ligated (or can be tied with a slipknot) using a 6-0 polypropylene suture for a 25-minute ischemic period [15]. After a 25-min ischemia, by Microsurgical scissors are used to cut the knot in the ligature (or by releasing the slipknot) the heart was reperfused for 2 h. Immediately after finishing the reperfusion time the rat was sacrificed, starting by injection of high dose from ketamine and xylazine, after giving good time for the animal to go into deep anesthesia, the rat is positioned and the chest is opened in flap like manner revealing the heart then a needle of the syringe is introduced into right ventricle to aspirate around 2 ml of blood for later plasma analysis. After that hearts were rapidly removed for quantification of myocardial injury and apoptosis and biochemical studies [16].

### Experimental groups and protocols

After the two week of acclimatization the rats were randomized into 6 groups, 6 rates in each group as follow:

**Sham group:** rats underwent the same anesthetic and surgical procedures but without ligation of (LAD) coronary artery.

**Control group:** rats underwent myocardial ischemia for 25 minutes & reperfusion fore 2h by ligation of (LAD) coronary artery.

**Control vehicle group:** rats pretreated with normal saline (vehicle for Irbesartan) via i.p. rout and underwent myocardial ischemia for 25 minutes & reperfusion fore 2 hr. by ligation of LAD coronary artery.

### **Irbesartan treated group**

rats pretreated with Irbesartan 3mg/kg [17] via intraperitoneal injection [18] at 30 minutes before ligation of LAD coronary artery [19].

Dissolve Irbesartan in normal saline (18) and given in a dose (3mg/kg) via IP route at 30 min before occlusion of LAD, Irbesartan prepare immediately before injection.

#### Blood Sampling for measurement of plasma cTn-I

At the end of reperfusion collect the blood from the apex of heart, about 2 ml of blood was collected from the heart. The blood sample was placed in a tube containing disodium EDTA (22 mg/ml) as anticoagulant and mixed thoroughly then centrifuged at 3000 rpm for 15 min. Then it is used for the determination of plasma cTn-I.

*Tissue Preparation for measurement of (TNF  $\alpha$ , IL-1B, IL-6, MCP-1 and MIP-1 $\alpha$ )* Cardiac tissues, collected 120 minutes after reperfusion were homogenized in a solution containing 1:10(w/v) phosphate buffered saline that contain 1% triton X-100 and protease inhibitor cocktail [20] by using high intensity liquid processor, After homogenization, samples were centrifuged at 14,000 rpm for 20 min at 4°C [21] the supernatant was collected and used in TNF- $\alpha$ , IL-1B, IL-6, MCP-1 and MIP-1 $\alpha$  measurement using commercially available ELISA kits (Signosis) according to the manufacturer's instructions.

#### Histopathological analysis and damage score

Tissues were fixed in 4% paraformaldehyde and embedded in paraffin. Sections were stained with hematoxylin and eosin for histological evaluation of tissue damage. In order to have a quantitative estimation of cardiac damage, sections (n=6 for each animal) were scored by 2 independent observers blinded to the experimental protocol. The following morphological criteria were considered: score 0, no damage; score 1 (mild), interstitial edema and focal necrosis; score 2 (moderate), diffuse myocardial cell swelling and necrosis; score 3 (severe), necrosis with the presence of contraction bands and neutrophil infiltrate; and score 4 (highly severe), widespread necrosis with the presence of contraction bands, neutrophil infiltrate, and hemorrhage.

#### Determination of myocardial apoptosis

Myocardial apoptosis was based on the staining of condensed chromatin in apoptotic nuclei. Since chromatin condensation in compact masses is the most specific and definite hallmark of apoptosis. Procedure is based on the selective denaturation of DNA in apoptotic cells by formamide, and detection of denatured DNA with monoclonal antibody to single-stranded DNA (ssDNA). Formamide is a gentle agent that denatures DNA in apoptotic cells, but not in necrotic cells or in the cells with

DNA breaks in the absence of apoptosis. The sensitivity of DNA in apoptotic cells to formamide is not related to DNA breaks, but rather reflects changes in chromatin associated with apoptosis, such as chromatin condensation and digestion of proteins stabilizing DNA. The assay includes attachment of cells to 96-well plates, treatment of attached cells with formamide, and staining of ssDNA in apoptotic cells with a mixture of primary antibody and peroxidase-labeled secondary antibody. The protocol based on the one-step detection of ssDNA with antibody mixture has higher sensitivity and lower number of steps than standard two-step immunostaining. This mixture is included in the kit in a ready to use form. The detection of apoptotic cells with formamide-mAb procedure is based on the staining of condensed chromatin in apoptotic nuclei. Since chromatin condensation in compact masses is the most specific and definite hallmark of apoptosis, this method provides universal detection of apoptosis. The apoptotic events that occur without DNA breaks or without activation of specific caspases will be detected with our mAb to ssDNA.

#### Statistical Analysis

Statistical analyses were performed using SPSS 20.0 for windows. Inc. Data were expressed as mean  $\pm$  SEM. Analysis of Variance (ANOVA) was used for the multiple comparisons among all groups followed by post-hoc tests using LSD method. The histopathological grading of heart changes is a non-normally distributed variable measured on an ordinal level of measurement; therefore non-parametric tests were used to assess the statistical significance involving this variable. The statistical significance of difference in total score between more than 2 groups was assessed by Kruskal-Wallis test, while Mann-Whitney U test was used for the difference between 2 groups. In all tests,  $P < 0.05$  was considered to be statistically significant.

#### Results

##### *Irbesartan reduced myocardial cytokines level following I-R injury*

Myocardium levels of inflammatory cytokines following I-R were analyzed by ELISA. Shows that I-R injury increased significantly the levels of myocardium TNF $\alpha$ , IL-1 $\beta$  and IL-6 as in (fig. 1A, B, C) compared with the sham group. In the Irbesartan treatment group, myocardium levels of TNF- $\alpha$ , IL-1 $\beta$  and IL-6 were reduced significantly compared with the control group ( $P < 0.05$ ).

##### *Irbesartan reduced chemokine following I-R injury*

Myocardium levels of inflammatory chemokine following I-R were analyzed by

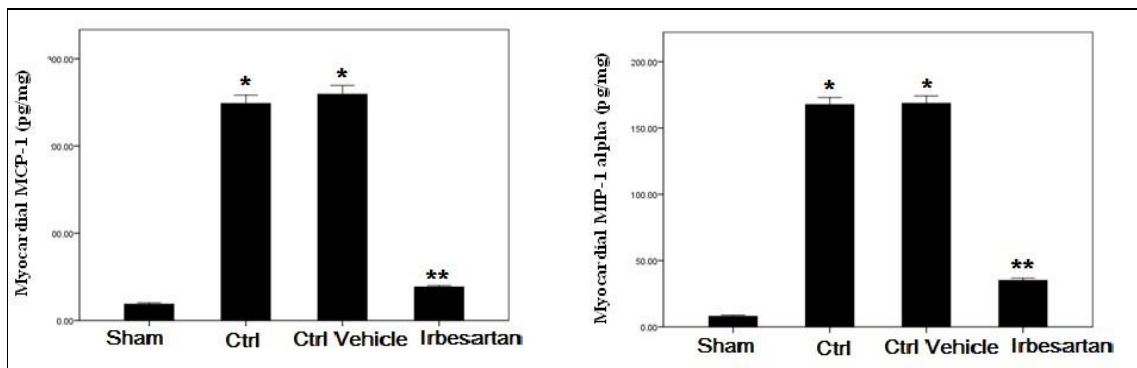
ELISA. I-R injury increased significantly the levels of myocardium MCP-1 and MIP1 alpha compared with the Sham group. While the Irbesartan treatment group, myocardium levels of MCP-1 and MIP-1 alpha were reduced significantly compared with the control group as in (fig. 2).

##### *Histological finding*

Treatment of rats with Irbesartan improved cardiac injury significantly as compared with control vehicle group and the total severity score mean of this group showed 16.7 % of the group had no damage and 50% had mild cardiac injury and 33.3% had moderate cardiac injury. A cross section of sham rat's heart showed a normal cardiac structure as in (fig. 3). All rats in this group showed normal hearts 100% as shown in table (1). There was statistically insignificant difference between control vehicle (1) group (III) and control group (II) and the total severity scores of the control group showed 16.7% of the group had moderate cardiac injury, 66.7% had severe cardiac injury and 16.7% had highly severe cardiac injury.

*Irbesartan alleviated myocardial injury following I-R injury*

Substantial evidence suggests apoptosis plays a critical role in cardiomyocyte loss and subsequent development of cardiac dysfunction after I-R injury, the level of myocardial ssDNA fragmentation significantly decreases in Irbesartan treated group as compared with control group as in (fig. 4). Further, the level of cTn-I significantly reduced after treated with Irbesartan (fig. 5)



**Figure 2.**

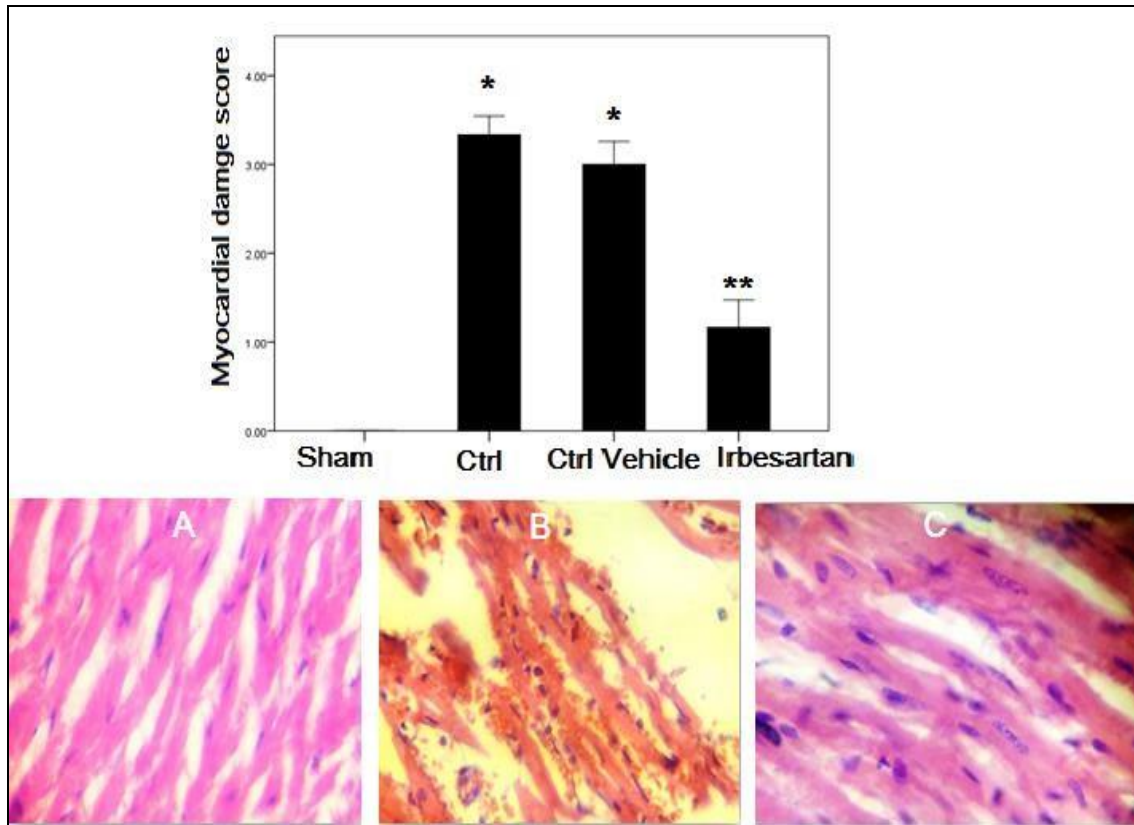
**Levels of chemokine after myocardial I-R**

Heart subjected to I-R showed increased mean of myocardial MCP-1 and MIP-1 alpha level (pg/mg) in the four experimental groups at the end of the experiment; \*P < 0.05 vs. Ctrl, \*\*P < 0.05 vs. Ctrl vehicle.

Categories	Sham		Control*		Control Vehicle*		Irbesartan**	
Normal	6	100%	0	0	0	0	1	16.7%
Mild	0	0	0	0	0	0	3	50%
Moderate	0	0	0	0	1	16.7%	2	33.3%
Sever	0	0	4	66.7%	4	66.7%	0	0
Very Sever	0	0	2	33.3%	1	16.7%	0	0
<b>Total</b>	<b>6</b>	<b>100%</b>	<b>6</b>	<b>100%</b>	<b>6</b>	<b>100%</b>	<b>6</b>	<b>100%</b>

**Table 1.**

Heart subjected to I-R showed show difference in histopathological scoring; \* $P < 0.05$  vs. Ctrl, \*\* $P < 0.05$  vs. Ctrl vehicle.



**Figure 3.**

Error bar chart shows the difference in mean  $\pm$  SEM values of total severity scores in the four experimental groups. Representative photomicrograph of a section of the heart tissue section stained with haematoxylin and eosin (X 40). **A/** The sham group shows normal architecture (score 0); no interstitial edema, no diffuse myocardial cell swelling and necrosis, no neutrophils infiltration, no hemorrhage, no capillary compression and no evidence of apoptosis. **B/** Photomicrograph of cardiac section for the control group showed hemorrhage, necrosis and neutrophil infiltration. **C/** Photomicrograph of cardiac section in Irbesartan treated group. Show almost normal cardiac structure. Most tissues reveal mild histological changes; \* $P < 0.05$  vs. Ctrl, \*\* $P < 0.05$  vs. Ctrl vehicle.



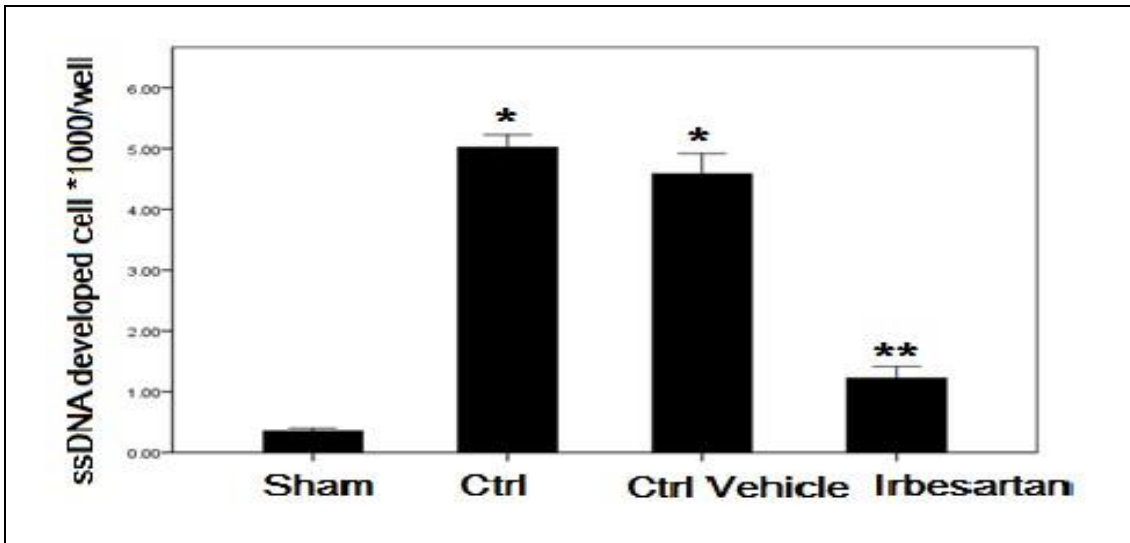


Figure 4.

Heart subjected to I-R showed increased the mean of ssDNA fragmentation (ssDNA developed cell \* 1000/well) in the four experimental groups at the end of the experiment; \* $P < 0.05$  vs. Ctrl, \*\* $P < 0.05$  vs. Ctrl vehicle.

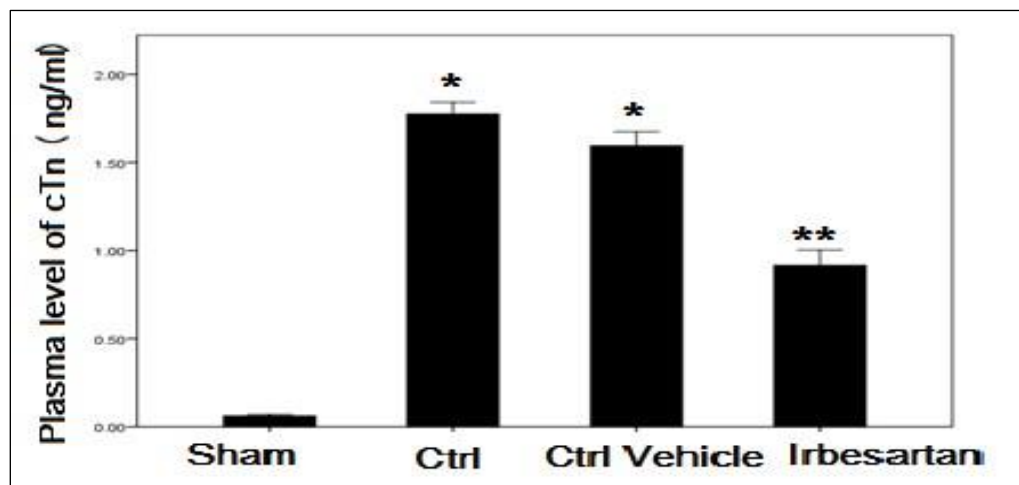


Figure 5.

Heart subjected to I showed increased the mean of cardiac troponin in the four experimental groups at the end of the experiment; \* $P < 0.05$  vs. Ctrl, \*\* $P < 0.05$  vs. Ctrl vehicle.

## Discussion

The major findings of the present study are as follows. Firstly, that the inflammatory cytokine (TNF- $\alpha$ , IL-1 $\beta$ , IL-6), chemokine (MCP-1, MIP-1 $\alpha$ ) and apoptosis play important role in the pathology of myocardial I-R. Secondly, Irbesartan pretreatment played a protective role against myocardial I-R injury, the protective effects of Irbesartan during myocardial I/R injury were correlated with the attenuation of inflammation and apoptosis. Thirdly, Irbesartan ameliorate myocardial I/R injury as evidenced by reduce the release of cardiac specific enzyme troponin I and myocardial damage.

Coronary arterial occlusion due to thrombosis after atherosclerotic plaque rupture is the major cause of myocardial infarction. These acute events represent the leading cause of death worldwide. Early reperfusion is the best method to salvage the ischemic organ; however, it leads to additional damage known as reperfusion injury [22]. The early reperfusion phase is characterized by enhanced release of ROS from endothelial cells and cardiomyocytes, as well as enhanced expression of cytokines and adhesion molecules, The enhanced expression of chemokines during the first hours of reperfusion triggers further recruitment of neutrophils and monocytes into the infarcted myocardium which lead to increase the cardiac damage by further releasing ROS, inflammatory mediators and proteases [23]. Further, cardiac TNF-alpha was significantly reduced in myocardial infarction in rats receiving Irbesartan ( $P < 0.01$ ) [24]. Moreover, Irbesartan improved residual LV end-diastolic pressure under both basal conditions and after volume overload ( $P < 0.01$ ). Other study showed that treatment with Irbesartan and/or lipoic acid to patients with the metabolic syndrome improves endothelial function and is associated with statistically significant reductions in plasma levels of interleukin-6 and plasminogen activator-1 [25]. Furthermore, in recent data showed that blockade of AT1 receptors by Irbesartan treatment strikingly down-regulated the mRNA expressions of inflammatory cytokines MCP-1, IL1 $\beta$  and IL6 in aortas of WT mice while significantly up-regulated the protein and mRNA expression of ACE2 which has recently been identified as a specific Ang II-degrading enzyme but its role in vascular biology remains elusive [26].

Irbesartan are exerts more beneficial effects on ischemic brain damage with an MCP-1 receptor blocker, due to its inhibitory effects on MCP-1/CCR2 signaling beyond AT(1) receptor blockade [27]. Form other hand AT1 receptor antagonists stimulate nitric oxide release in rat platelets and HUVECs [28]. Increased nitric oxide release in the presence of AT1 receptor antagonists may decrease MCP-1 levels because nitric oxide has been shown to inhibit MCP-1 production [29]. The potential cardio-protective effect of Irbesartan against acute myocardial infarction induce in experimental model of metabolic syndrome & their result showed decrease in MCP-1, MIP-1alpha as compared with un treated group [30].

To the best of our knowledge, there is no data available about effect of Irbesartan on cTn-I in regional ischemia reperfusion injury by ligation of LAD coronary artery. However, in study of other model showed that the AT-II blocker Irbesartan was able to reduce troponin I raise in experimental atrial fibrillation [31]. There is a strong correlation between intracellular Angiotensin II staining and Angiotensin II-induced apoptosis for all compared groups. He concluded that internalization of Angiotensin II is involved in apoptosis of vascular smooth muscle cells and they showed that The



Angiotensin AT(1) receptor antagonist Irbesartan decreased Angiotensin II-mediated apoptosis which assessed by DNA fragmentation, cell cytometry and caspase-3 activity [32].

Many authors presented that Irbesartan, an AT1 receptor blocker, reduced the skeletal-myocyte apoptosis in an animal model of congestive heart failure, suggesting that angiotensin II-induced skeletal myocyte apoptosis too is mediated by the AT1 receptor [33]. The AT1 receptor antagonist was effective in reducing myocardial reperfusion injury *in vivo*. This effect can at least be partially attributed to the attenuation of cardiomyocyte apoptosis, and this anti-apoptotic effect appears to be related to the increased expression of Bcl-2 and alteration in MAP kinase signaling [34]. Some studied showed that the effect & mechanism of Irbesartan on cardiac myocyte apoptosis in myocardial ischemia reperfusion injury with isolated rat hearts subjected to ischemia for 30 minutes followed by reperfusion for 60 minutes he concluded that Irbesartan can protect the heart from ischemic and reperfusion injury by decreasing myocyte apoptosis [35].

In conclusion, this study reveal that Irbesartan may ameliorate myocardial I/R injury in rats via interfering with inflammatory reactions and apoptosis which induced by I/R injury.

### Competing interests

The authors have declared that no competing interests.

### Author Contributions

NH (corresponding author) was responsible for the study design, the statistical analysis and the writing of the manuscript. FA and SZ were involved in the execution of the measurements, design, and statistical analysis and editing of the manuscript. All authors read and approved the final manuscript

### References

1. Nichols H. Estrogen is the primary female sex hormone. Among other roles, it promotes the development and maintenance of female characteristics in the human body. MNT 206;
2. National Academy of Science. Estrogen affects IVF success Web MD, 2016
3. Borawski D, Bluth MH. Reproductive function and pregnancy. In: McPherson RA, Pincus MR, eds. Henry's Clinical Diagnosis and Management by Laboratory Methods. 22nd ed. Philadelphia, PA: Elsevier Saunders; 2011:chap 25.
4. Carmina E, Stanczyk FZ, Lobo RA. Laboratory assessment. In: Strauss JF, Barbieri RL, eds. Yen and Jaffe's Reproductive Endocrinology. 7th ed. Philadelphia, PA: Elsevier Saunders; 2014:chap 34.
5. Gruber HA, Farag AF. Evaluation of endocrine function. In: McPherson RA, Pincus MR, eds. Henry's Clinical Diagnosis and Management by Laboratory Methods. 22nd ed. Philadelphia, PA: Elsevier Saunders; 2011:chap 24.

6. Lin Y, Lan K, Huang F, et al. Reproducibility and clinical significance of pre-ovulatory serum progesterone level and progesterone/estradiol ratio on the day of human chorionic gonadotropin administration in infertile women undergoing repeated in vitro fertilization cycles. *Reproductive Biology and Endocrinology* 2015;13:41.
7. Boon J. Study redefines role of estrogen in cervical cancer. National Cancer Institute (NCI) and the University of Oklahoma Health Sciences Center 2015.
8. Foster J. Natural protection against estrogen overload. 2000.



**American Journal of BioMedicine**

Journal Abbreviation: AJBM  
ISSN: 2333-5106 (Online)  
DOI: 10.18081/issn.2333-5106  
Publisher: BM-Publisher  
Email: [editor@ajbm.net](mailto:editor@ajbm.net)

