

<http://dx.doi.org/10.18081/2333-5106/018-10/635-647>

Incidence of left ventricular thrombus formation in acute and chronic anteroseptal myocardial infarction

Haider Sobhy Al Hadad ^{1*}

Abstract

The objective of this study is to determine the incidence of left ventricular thrombus formation in both acute and old anteroseptal myocardial infarction. This prospective study was performed through 51 patients (age range 21-85 years, 34 males and 17 females) with AAMI and 92 patients (age range 43-90 years, 70 males and 22 females) with OAMI at Al- Hussain Teaching Hospital in Karbala and privet clinic from March 2015 to April 2017. Transthoracic echocardiographic study was performed within the first month of AAMI and for OAMI (one echo study for every patient). The incidence of LVT in AAMI was 5.9% while for OAMI was 4.3% and for both AAMI and OAMI was 4.9%. For the AAMI and OAMI cases, the patients mean age was 55.65 ± 11.03 and 63.70 ± 11.33 year respectively. Thirty eight percent of the patients were smokers, and smoking was significantly more among AAMI cases and it was more in male patients. Fifty-six percent of the patients were hypertensive, and fifty-three percent had diabetes mellitus. Both hypertension and diabetes mellitus were significantly more among females. No significant causal association between smoking, hypertension (HT) and diabetes mellitus (DM) with development of LVT in both AAMI and OAMI. In this study the incidence of LVT after AAMI and OAMI was relatively low, for more accurate detection of LVT by transthoracic echo (TTE) need serial echo study pre and post-hospital discharge.

Keywords: AAMI; LVT; AMI; OAMI

*Corresponding author email: haider_hadad@yahoo.com

¹Department of Medicine/Kerbala College of Medicine/ University of Kerbala

Received March 26, 2020; Accepted June 22, 2020; Published July 26, 2020

Copyright © 2020 HA. This is an article distributed under the terms of the Creative Commons Attribution License (<http://creativecommons.org>), which permits unrestricted use, distribution, and reproduction in any medium, provided the original work is properly cited.



Introduction

Left ventricular thrombus is a recognized problem in various cardiac conditions and mainly seen in acute anterior myocardial infarction and congestive heart failure (CHF) as a consequence of severe left ventricular (LV) systolic dysfunction [1, 2]. Now, the incidence of LVT formation following AMI is lower (5%–10%). This is owing to the extensive use of rapid mechanical reperfusion and potent new antiplatelet and antithrombotic agents [2, 3]. Solheim and his colleagues reported an incidence of 15% within 3 months of AMI in selected patients managed with primary percutaneous coronary intervention (PCI) [4]. The collection, of endothelial injury, hypercoagulability, and blood stagnation, which are

described previously as Virchow's triad, is accountable for the formation of thrombus [5]. In AMI, other predisposing factors are big infarct size, severe apical a synergy, LV aneurysm and anterior MI [6]. There is evidence that LVT frequently develop within a few days after AMI [7-9]. Transthoracic echo (TTE) is still the widely used modality in the diagnosis of LVT because of its access, safety, and ease. It has been verified to have a sensitivity of 90–95% and specificity of 85–90% in a setting of adequate imaging [10, 11]. On the other hand, false positive findings should be taken in consideration. These are caused by endocardial elastosis, trabeculae, false tendons near-field clutter, and artifacts [12, 13]. Currently delay enhancement cardiac magnetic resonance imaging (CMR) is considered the gold standard for early and proper diagnosis of LVT after AAMI. Cardiac MRI with delayed enhancement has 88% to 91% sensitivity and 99% specificity to detect left ventricular thrombosis [14,15]. However, compared with echocardiography, routine cardiac MRI is time-consuming, expensive, and not readily available. The risk of thromboembolic complications from LVT was about 10% in the prethrombolytic era, while the risk was (2– 3%) in the thrombolytic era and its much lower [2]. In this prospective study, the demographic and other characteristics of the patients were reviewed with LVT, undergoing echocardiography at the Al- Husain Teaching Hospital and private clinic over a two-year period to determine the significance of each predictor aiming to put forward the main guidelines in managing these cases.

Methodology

Fifty-one patients were diagnosed with AAMI and 92 patients with OAMI. These patients were examined by using non-contrast TTE at Al Husain Teaching Hospital in Karbala/ Iraq, from 1st March 2015 to 30th April 2017. Data sheet was designed comprising patients' age, gender, associated comorbidities, and echocardiographic indices. The echocardiography was done using Vivid9 ultrasound machine (GE Medical Systems) and Phillips ultrasound machine (clear view 350). The diagnosis of LVT was reached when a mass was noted next to the myocardium on multiple plane views throughout the cardiac cycle and associated regional wall motion abnormalities [1, 13]. Regional wall motion abnormality was considered present if hypokinesia, akinesia, and dyskinesia were observed in at least two segments of the left ventricular wall or if the left ventricular aneurysm is observed. Old infarct was diagnosed in the presence of segmental thinning, LV remodeling and fibrosis [13]. The patients were classified into two groups; those with AAMI within one month of the onset of MI, the other group are those with OAMI after more than one month of the onset. The documented risk factors for myocardial infarction are age, gender, diabetes mellitus, hypertension, smoking and these factors were included in determining the risk factors in the studied sample [16]. Diagnosis of myocardial infarction was based on the combination of a documented history of acute chest pain, ECG abnormalities, cardiac markers and segmental wall abnormalities [17]. Inclusion criteria of the LVT group were hospitalized AAMI and OAMI patients with or without LVT before discharge and patients from private clinic. Exclusion criteria were thrombotic hematological disorders, atrial fibrillation, dilated cardiomyopathy (DCM) and severe valvular heart disease. Data was analyzed using SPSS Von 21 Chicago, IL,

USA. Mean \pm SD was derived for continuous variables and comparison was made using Student's t-test. A P value of <0.05 was considered significant.

Results

The incidence of OAMI was 65.4% while that of AAMI was 47.5%. The study explored both acute and old anteroseptal myocardial Infarction patients' characteristics admitted to Al Hussein hospital in Karbala/Iraq in two years. For all cases, the patients' age ranged between 21 and 90 years with a mean age of 60.83 ± 11.84 years Table 1. Females constitute 27.3% of the sample and no significant gender distribution was found between acute and old cases ($p=0.226$) Figure 1. There was no significant difference in the patients' age regarding gender with a mean age of 60.69 ± 12.36 years for females and 60.88 ± 11.70 year for males. A significant difference was found between the mean age of acute and old anterior Infarction patients ($p=0.017$) Table 1. Thirty-eight percent of the whole sample were smokers, and it was significantly more among AAMI cases compared to OAMI (49% vs.31.5%, $p=0.039$). Fifty-six percent of the patients were hypertensive, and nearly the same proportion had diabetes mellitus (53.8%). Both hypertension and diabetes mellitus were significantly more prevalent among females. The incidence of hypertension among females was 74.4% vs. 49% among males ($p= 0.007$). Diabetes mellitus showed a significantly higher incidence among females 76.9% vs. 45.2% ($p=0.001$). As expected, smoking was mainly a male behavior 47.1% vs. 12.8% ($p<0.001$). For the AAMI cases, the patient's ages ranged between 21 and 85 years with a mean age of 55.65 ± 11.05 years. Females formed 33.3% of the sample Figure 1. Forty-nine percent of the patients were smokers 56.9% were hypertensive and 45% had diabetes mellitus. There was no significant age difference regarding gender with the mean age for females being 55.23 ± 12.24 years, while for males the mean was 55.85 ± 10.58 year. For the OAMI cases, the patient's age ranged between 43 and 90 years with a mean age of 63.70 ± 11.33 year. Females account for 23.9% of the sample Figure 1. Thirty-one percent of the patients were smokers and 55% of the patients were hypertensive and 58.7% had diabetes mellitus. There was no significant gender difference in the patients' age with a mean age of 64.91 ± 10.93 years for females and 63.31 ± 11.51 years for males. The incidence of LVT formation was 3 per 51 patients with AAMI (5.8%) all of them were men. While it was 4 per 92 cases of OAMI (5%), also, all LVT cases were men. Thus, there was no significant difference in the incidence of LVT between AAMI and OAMI groups, $p\text{-value}> 0.05$ Table 1.

Table 1.

The demographic characteristics of acute and old anterior MI patients in Imam Husain Teaching hospital in Karbala/Iraq in; 2015-2016.

Variable	Category	Acute ant. MI		Old ant. MI		Total		p-value
		Freq.	Percent	Freq.	Percent	Freq.	Percent	
Gender	Male	34	66.7	70	76.1	104	72.73	0.226
	Female	17	33.3	22	23.9	39	27.27	
Age	20-49 year	14	27.451	11	11.9565	25	17.5	0.017
	50-59 year	13	25.4902	24	26.087	37	25.9	
	60-69 year	19	37.2549	30	32.6087	49	34.3	
	70-79 year	4	7.84314	15	16.3043	19	13.3	
	80 year or more	1	1.96078	12	13.0435	13	9.1	
Smoking	No	26	51	63	68.5	89	62.2	0.039
	Yes	25	49	29	31.5	54	37.8	
Hypertension	No	22	43.1	41	44.6	63	44.1	0.118
	Yes	29	56.9	51	55.4	80	55.9	
Diabetes mellitus	No	28	54.9	38	41.3	66	46.15	0.869
	Yes	23	45.1	54	58.7	77	53.85	
Left Ventricle Thrombosis		3	5.9	4	4.3	7	4.9	0.911

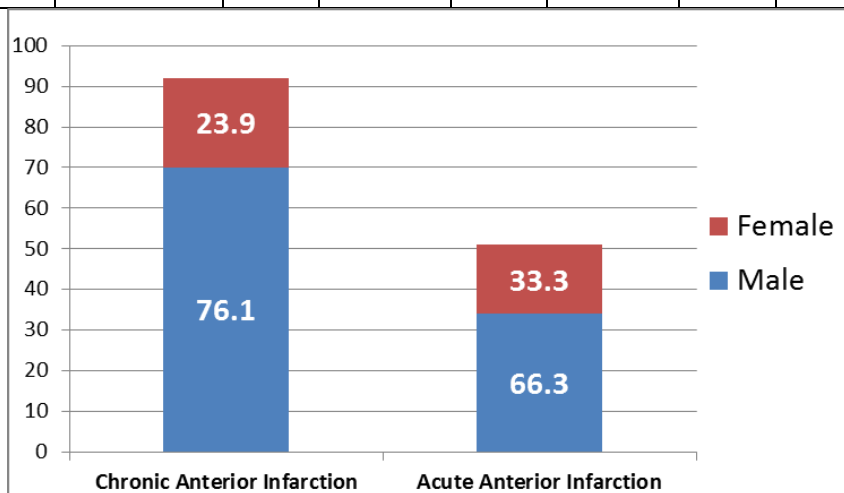


Figure 1

The gender distribution of Acute and Old anterior Infarction patients admitted to Al Hussein hospital in Karbala/Iraq between 2015 and 2016.

Table 2.

The gender distribution of acute and Old anteroseptal Infarction patients admitted to Al Hussein hospital in Karbala/Iraq between 2015 and 2016 ($n=143$).

Variable	Categories	Male		Female		Total		Chi-square value	Significance
		Freq	%	Freq	%	Freq	%		
Smoking	Smoker	49	47.1	5	12.8	54	37.8	14.19	<.001
	Non-smoker	55	52.9	34	87.2	89	62.2		
Symptoms	Chest pain	50	48.1	20	51.3	70	49	0.12	0.728
	Shortness of Breath (SOB)	16	15.4	5	12.8	21	14.7	0.15	0.7
	Palpitation	27	26	12	30.8	39	27.3	0.33 (all 1.35)	0.567 (all .717)
	Orthopnea	11	10.6	2	5.1	13	9.1	1.1	0.315
Hypertension		51	49	29	74.4	80	55.9	7.38	0.007
Diabetes mellitus		47	45.2	30	76.9	77	53.8	11.49	0.001
Received thrombolytic treatment		15	14.4	6	15.4	21	14.7	0.02	0.885
Echo -EF (<40%)		2	1.8	0	0	2	1.4	0.76	0.385
Number of thrombi	Single	7	6.7	0	0	7	4.9	0.93	0.334
Positive Troponin test		42	40.4	18	46.2	60	42	0.39	.534
Medication*	1	21	20.2	14	35.9	35	24.5	1.93 (all 5.82)	0.165 (all.329)
	3	1	1			1	0.7		
	4	15	14.4	3	7.7	18	12.6	1.16	0.278
	5	12	11.5	5	12.8	17	11.9	0.04	0.833
	6	38	36.5	14	35.9	52	36.4	0.01	0.943
	7	17	16.3	3	7.7	20	14	1.75	0.184

The analysis of all cases ($n=143$) showed that 49% of the cases presented with chest pain, while 27% presented with palpitation. There was no significant difference in the incidence of symptoms between males and females. History of hypertension and diabetes mellitus was significantly higher among female patients Table 2. However, no significant gender difference was found for all the other variables (thrombolytic therapy, ejection fraction (EF <40%), positive troponin test, and medication

Table 2.

Starting medications had a significant positive strong correlation with positive troponin test ($p < .001$), while the later showed significant correlation with gender ($p < .001$). For the other variables, a significant negative correlation was found between age and smoking ($p < .001$), and diabetes mellitus ($p = .001$), and with thrombolytic therapy ($p = .008$), and with ejection fraction ($EF < 40\%$) ($p = .001$). A significant negative correlation was found between diabetes mellitus and smoking ($p < .001$). In recent anterior myocardial infarction there was significant association between different variables included in the study. There was no significant difference in the presenting symptoms between males and females. Patient's age had a significant positive correlation with the Positive Troponin test ($r = 0.25$, $p = .042$), while no significant correlation found with gender ($r = 0.1$, $p = .485$), Table 2. The causative association between selected risk factors, namely, current smoking, hypertension and diabetes with the development of LVT was studied and results are shown in Table 3. Owing to these findings, smoking has a positive causal association with LVT though the result was not significant.

Table 3.

Association between smoking, hypertension and diabetes with the development of left ventricular thrombus.

	Smoking vs LVT		HT vs LVT		DM vs LVT	
	AAMI	OAMI	AAMI	OAMI	AAMI	OAMI
Odds ratio	2.1739	1.0426	0.3793	0.0787	0.59	0.21
95 % CI:	0.18 to 25.6	0.14 to 7.70	0.03 to 4.45	0.004 to 1.5	0.05 to 6.96	0.0214 to 2.14
Z statistic	0.617	0.041	0.771	1.687	0.418	1.312
Significance level	P = 0.53	P = 0.96	P = 0.44	P = 0.09	P = 0.67	P = 0.18

Discussion

Positive relationship between the number of ultrasonic examinations performed and the reported incidence of LV thrombus [28-31]. Another, study conducted by Mir JU, and his colleagues also demonstrates a high incidence of LVT after AAMI (43%) [32]. Another study was conducted by Phillipe Meurin, and his colleagues on incidence, diagnostic techniques, and evolution of LVT in patients with anterior myocardial infarction using TTE and CMR with contrast-delayed enhancement (CMRDE) in detecting LVT. The result was 26% for LVT and the accuracy of TTE is significant as compared with CMRDE [33]. Another study was undertaken by Ebrahimi M and his colleague also demonstrates high incidence of LVT after AAMI 35,3 (34%). This study went through several limitations. It was not feasible to evaluate the outcome of LVT in the patients, because of the difficulty of follow up. In addition, no serial echo study was performed for the patients with LVT for the same reason. Given the higher accuracy of contrast echo for the detection of LVT, the incidence reported in the study may be underestimated, as some cases of laminar and small thrombi might have been missed. Similarly,

echocardiographic studies might not have been focused on detection of LVT in some cases, resulting in low yield. In our study no, significant association between smoking and LV thrombus in both AAMI and OAMI and this where comparable to other study done by Cindy L. Grines and his colleagues on effect of cigarette smoking on outcome after thrombolytic therapy for myocardial infarction [35]. On the other hand, other studies done by Tsuyoshi Honda and his colleagues and study done by Yao-Jun Zhang and his colleagues on effect of current cigarette smoking on outcome of AAMI and old OAMI shows bad outcome [36, 37]. In our study no significant causal association between DM, HT and LV thrombus in both AAMI and OAMI while another study done by Mao-Jen *et al*, on impact of diabetes and hypertension on cardiovascular outcomes in patients with coronary artery disease receiving percutaneous coronary intervention shows significant association of DM with bad outcome in AAMI and OAMI while no significant association of HT with bad outcome in AAMI and OAMI [38]. Our study, results comparable to another study done Chiara Lazzeri *et al*, on Impact of hypertension on short- and long-term prognoses in patients with ST elevation myocardial infarction and without previously known diabetes which shows no significant effect of HT on short and long term outcome in patient with AAMI and OAMI [39].

In Conclusion, in the recent years the incidence of LV thrombus post anterior MI is lower than before probably due to: early anticoagulation therapies in the acute phase; the size of infarction smaller; improved LV remodeling and early mechanical reperfusion. CMR-DE is currently considered the gold standard for assessing LVT. Furthermore, CMRDE is not available now in our hospital. Therefore, for detection of LVT in anterior MI with a better result we need early transthoracic echo after MI, serial echo pre-discharge from the hospital and post-discharge echo study, because assessment of LVT shortly after the onset of myocardial infarction will miss LV thrombus formation.

Consent for publication

Not applicable.

Competing interests

The author declares that he has no competing interests

References

1. Habash F, Vallurupalli S. Challenges in management of left ventricular thrombus. *Ther Adv Cardiovasc Dis* 2017;11(8):203–213.
2. Delewi R, Zijlstra F, Piek JJ. Left ventricular thrombus formation after acute myocardial infarction. *Heart* 2012;98:1743–9.
3. Shacham Y, Leshem-Rubinow E, Ben Assa E, et al. Frequency and correlates of early left ventricular thrombus formation following anterior wall acute myocardial infarction treated with primary percutaneous coronary intervention. *Am J Cardiol*.2013; 111:667–70.

4. Solheim S, Seljeflot I, Lunde K, et al. Frequency of left ventricular thrombus in patients with anterior wall acute myocardial infarction treated with percutaneous coronary intervention and dual antiplatelet therapy. *The American Journal of Cardiology* 2010;106:1197–1200.
5. A. Nair, B. Sealove, J. L. Halperin, G. Webber, and V. Fuster, "Anticoagulation in patients with heart failure: who, when, and why?" *European Heart Journal*, 2006;8:E32–E38.
6. Weinsaft JW, Kim HW, Crowley AL, et al. LV thrombus detection by routine echocardiography: insights into performance characteristics using delayed enhancement CMR. *Journal of the American College of Cardiology* 2011;4:702-712.
7. Visser CA, Kan G, David GK, Lie KI, Durrer D. Two-dimensional echocardiography in the diagnosis of left ventricular thrombus. A prospective study of 67 patients with anatomic validation. *Chest* 1983;83:228-232.
8. Weinreich DJ, Burke JF, Pauletto FJ. Left ventricular mural thrombi complicating acute myocardial infarction. Longtermfollow-up with serial echocardiography. *Ann Intern Med* 1984;100:789-794.
9. Asinger RW, Mikell FL, Elspenger J, Hodges M. Incidence of left ventricular thrombosis after acute transmural myocardial infarction. Serial evaluation by two-dimensional echocardiography. *N Engl J Med* 1981;305:297302.
10. Visser CA, Kan G, David GK, Lie KI, Durrer D. Two dimensional echocardiography in the diagnosis of left ventricular thrombus. A prospective study of 67 patients with anatomic validation. *Chest* 1983;83:228–232.
11. Srichai MB, Junor C, Rodriguez LL, et al. Clinical, imaging, and pathological characteristics of left ventricular thrombus: a comparison of contrast-enhanced magnetic resonance imaging, transthoracic echocardiography, and trans esophageal echocardiography with surgical or pathological validation. *American Heart Journal* 2006; 152:75–846.
12. Armstrong WF, Ryan T. Masses, tumors and source of embolism," in Feigenbaum's *Echocardiography*, pp. 711–740, Lippincott Williams & Wilkins, Philadelphia, Pa, USA, 7th edition, 2010.
13. Weinsaft JW, Kim RJ, Ross M, et al. Contrastenhanced anatomic imaging as compared to contrast-enhanced tissue characterization for detection of left ventricular thrombus. *Journal of the American College of Cardiology. Cardiovascular Imaging* 2009; 2:969–979.
14. Mollet NR, Dymarkowski S, Volders W, et al. Visualization of ventricular thrombi with contrast-enhanced magnetic resonance imaging in patients with ischemic heart disease. *Circulation* 2002;106:2873–2876.
15. Srichai MB, Junor C, Rodriguez LL, et al. Clinical, imaging, and pathological characteristics of left ventricular thrombus: a comparison of contrast-enhanced magnetic resonance imaging, transthoracic echocardiography, and transesophageal echocardiography with surgical or pathological validation. *Am Heart J* 2006;152:75–84.
16. Petter libby.the pathogenesis, prevention, and treatment of atherosclerosis. SectionV: chapter 30: p.346. *Harrisons Cardiovascular Medicine* 2nd Edition, 2013.
17. Armstrong WF, Ryan T. Echocardiography and coronary artery disease, in Feigenbaum's *Echocardiography*, pp. 427–472, Lippincott Williams & Wilkins, Philadelphia, Pa, USA, 7th edition, 2010.
18. American College of Cardiology/American Heart Association Task Force on Practice Guidelines (Committee on Management of Acute Myocardial Infarction). ACC/AHA Guidelines for the Management of Patients with Acute Myocardial Infarction *Am Coll Cardiol* 1996;28:1328–1428.
19. The Task Force on the Management of Acute Myocardial Infarction of the European Society of Cardiology. Acute Myocardial Infarction: pre-hospital and in-hospital management. *Eur Heart J* 1996;17:43–63.

20. Domenicucci S, Chiarella F, Bellotti P, et al. Long-term prospective assessment of left ventricular thrombus in anterior wall acute myocardial infarction and implications for a rational approach to embolic risk. *Am J Cardiol* 1999;83:519–524.
21. Keeley EC, Hillis LD. Left ventricular mural thrombus after acute myocardial infarction. *Clin Cardiol* 1996;19(2):83-86.
22. Osherov AB, Borovik-Raz M, Aronson D, et al. Incidence of early left ventricular thrombus after acute anterior wall myocardial infarction in the primary coronary intervention era. *Am Heart J* 2009;157:1074–80.
23. Gianstefani S, Douiri A, Delithanasis I, et al. Incidence and predictors of early left ventricular thrombus after ST-elevation myocardial infarction in the contemporary era of primary percutaneous coronary intervention. *Am J Cardiol* 2014;113:1111–6.
24. Shacham Y, Leshem-Rubinow E, Assa E, et al. Frequency and correlates of early left ventricular thrombus formation following anterior wall acute myocardial infarction treated with primary percutaneous coronary intervention. *Am J Cardiol* 2013;111: 667– 670.
25. Jiang YX, Jing LD, Jia YH. Clinical Characteristics and Risk Factors of Left Ventricular Thrombus after Acute Myocardial Infarction: A Matched Case-control Study. *Chin Med J* 2015;128:2415-9.
26. Vecchio et al. Postinfarction Ventricular Thrombus after Thrombolysis. *Circulation* 1991;84:512-519.
27. Davis MJ, Ireland MA. Effect of early anticoagulation on the frequency of left ventricular thrombi after anterior wall acute myocardial infarction. *Am J Cardiol* 1986; 57:1244–1247.
28. Funke Kupper AJ, Verheugt FW, Peels KH, et al. Left ventricular thrombus incidence and behavior studied by serial two dimensional echocardiography in acute myocardial infarction: left ventricular wall motion, syAAMic embolization and oral anticoagulation. *J Am Coll Cardiol* 1989;13:1514–1520.
29. Keren A, Goldberg S, Gottlieb S, et al. Natural history of left ventricular thrombi: their appearance and resolution in the posthospitalization period of acute myocardial infarction. *J Am Coll Cardiol* 1990;15:790–800.
30. Domenicucci S, Chiarella F, Bellotti P, et al. Long-term prospective assessment of left ventricular thrombus in anterior wall acute myocardial infarction and implications for a rational approach to embolic risk. *Am J Cardiol* 1999;83:519–524.
31. Mir JU, Raheel Jahangir J, Asfandyar Q, Sher Ali K, Syed Abbas A, Muhammad Zeeshan H. Left ventricular thrombus in patients with acute anterior wall myocardial infarction. *J Ayub Med Coll Abbottabad* 2014;26(4):491-5.
32. Meurin P, Carreira V, Dumaine R, et al. Incidence, diagnostic methods, and evolution of left ventricular thrombus in patients with anterior myocardial infarction and low left ventricular ejection fraction: a prospective multicenter study. *AHJ* 2015;170:256-262.
33. Ebrahimi M, Fazlinezhad A, Azari M, Abdar Esfahani M. Long-term clinical outcomes of the left ventricular thrombus in patients with ST elevation anterior myocardial infarction. *ARYA Atheroscler* 2015;11(1):1-4.
34. Grines CL, Topol EJ, O'Neill WW, Barry S, et al. Effect of Cigarette Smoking on Outcome After Thrombolytic Therapy for Myocardial Infarction. *Circulation* 1995;91:298-303.
35. Honda P, Fujimoto K, Miyao Y, et al. Current cigarette smoking is an independent risk factor for subacute stent thrombosis in acute myocardial infarction patients. *Journal of Cardiology* 2014;63:358-364.
36. Zhang Y, Javaid Iqbal, Klaveren D, et al. Smoking is Associated With Adverse Clinical Outcomes in Patients Undergoing Revascularization With PCI or CABG: The SYNTAX Trial at 5-Year Follow-Up. *Journal of the American College of Cardiology* 2015;65:1107-1115.

37. Lin M, Chen C, Lin H, Wu H. Impact of diabetes and hypertension on cardiovascular outcomes in patients with coronary artery disease receiving percutaneous coronary intervention. BMC Cardiovascular Disorders BMC series – open, inclusive and trusted 2017;17:12.
38. Lazzeri C, Valente S, Chiostrì M, et al. Impact of hypertension on short- and long-term prognoses in patients with ST elevation myocardial infarction and without previously known diabetes. Heart and Vessels 2012;27:370–376.



American Journal of BioMedicine

Journal Abbreviation: AJBM

ISSN: 2333-5106 (Online)

DOI: 10.18081/issn.2333-5106

Publisher: BM-Publisher

Email: editor@ajbm.net

