

<http://dx.doi.org/10.18081/2333-5106-014-04/69-72>

## Successful Macro-surgical Replantation of an amputated Penis

Salam Alhasani, M.D., M.R.C.S.I [salamalhasani@hotmail.com](mailto:salamalhasani@hotmail.com)

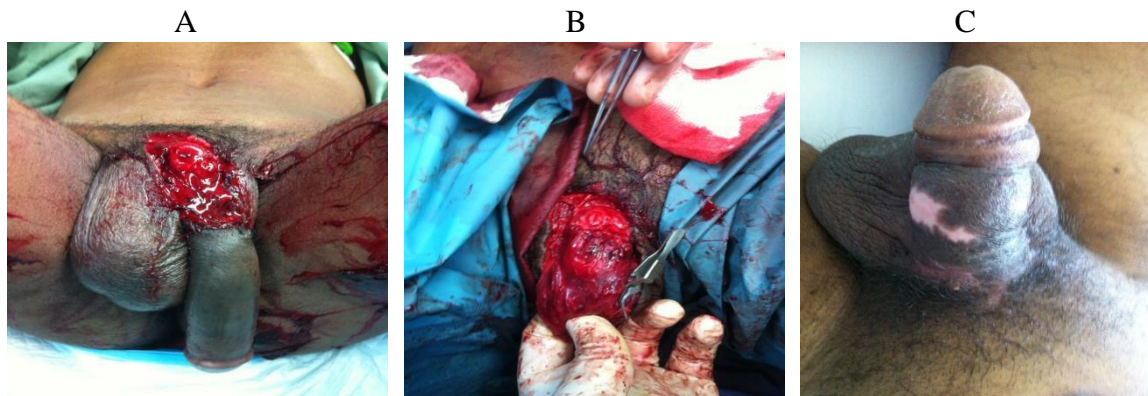
Dubai hospital, Urology Dept., Dubai hospital, UAE

Received 04 December 2013; accepted 23 March 2014; published 27 April 2014

Copyright © 2014 SH. This is an open access article distributed under the terms of the Creative Commons Attribution License (<http://creativecommons.org/licenses/by/4.0>), which permits unrestricted use, distribution, and reproduction in any medium, provided the original work is properly cited.

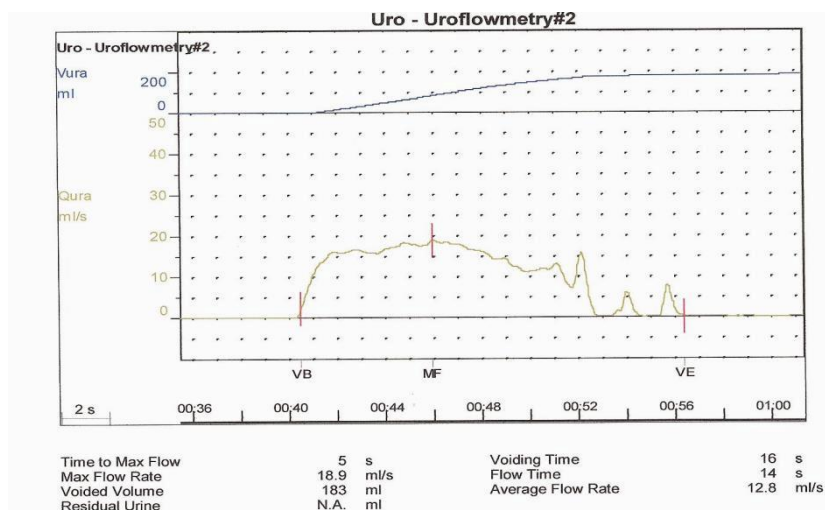
Total penile amputation is an uncommon injury [1-6]; 87% of the patients reported had psychiatric problems. Self-amputation of external genitals is known as Klingsor syndrome [47]. A few patients had poor gender identity feeling themselves inadequate as males. Some cases arise from felonious assault by jealous homosexual lovers [1, 6]. In 1970 in Thailand, an epidemic was seen, of penile amputation as punishment for philandering by humiliated wives [2-6]. Although replantation of the amputated penis has a high success rate, there may be some remaining squeals such as skin necrosis and urethral stricture or fistula [5], We report a case of a macroscopic replantation of an amputated penis.

30 years-old man, previously does not known to have a psychiatric illness, came in to the emergency room after attempting suicide by penile amputation with a razor blade. The time elapsed between amputation and arrival at the emergency room was about 3 hours. The amputated specimen had been found hanging with a thin skin flap in the ventral part (Figure 1). We found a clear-cut through all penile structures without major lacerations. The amputated penis was carefully cleaned until all visible contaminants and coagulated blood had been removed. There were diffuse bleedings from the cavernosal bodies and an arterial and venous bleeding from the dorsal vessels. Immediately a replantation of the amputated penis was attempted. We aligned the amputated part with the stump in as natural a position as possible. The septum that separated the two corpora cavernosa was sutured using 4-0 vicryl. Each corpus cavernosum was anastomosed using interrupted 4-0 vicryl sutures. The tunica albuginea was brought together using interrupted 4-0 vicryl sutures. The deep dorsal vein and one artery of the penis were anastomosed using 6-0 nylon sutures (Figure 2). Anastomosis of the urethra (after spatulation) together with the corpus spongiosum was then performed using 8 interrupted sutures of 4-0 vicryl. A 16-F silicone catheter was used as a splint. A suprapubic cystostomy was done to divert urine flow temporarily. The operative time was three hours.



**Figure 1.**

The amputated specimen hanging with a thin skin flap in the ventral part (A), Intra-operative, all corpora and penile vessels are re-anastomosed with pinkish color of tissues (B). 2-months post-operative revealed a normal-appearing penis with adequate erectile function (C).



**Figure 2.**

2-months post-operative revealed a normal-appearing penis with normal Voiding function.

Postoperatively, the patient received broad-spectrum antibiotics, Aspirin and lowmolecular-weight heparin. On the 2<sup>nd</sup> postoperative day, color Doppler ultrasonography of the penile shaft showed low-resistance arterial blood flow and normal venous flow distal to anastomosis. On day 5, a bilateral scrotal hematocoele occurred which treated conservatively. On day 9, another color Doppler ultrasonography of the penile shaft showed the same arterial and venous blood flows as observed on day 2. The completely penile skin remain intact a part from a minor superficial slough after blister formation. Three weeks later, the hematocoele

showed great reduction in size and scrotal ultrasound revealed minimal hematocele with normal both testes and color flow bilaterally. The Foley catheter was removed after 4 weeks, and retrograde urethrography showed no leakage or stricture therefore, the cystostomy tube was clamped and removed thereafter. Examination 2-months later revealed a normal appearing penis with adequate erectile function. Voiding function was normal (Figure 2).

### Discussion

The results of penile replantation efforts are related to at least 3 factors: the completeness of the amputation, time from amputation to re-plantation and the technique of replantation. Complete amputations, both experimental and clinical replanted without specific microvascular anastomosis, such as our case, most cases develop some degrees of skin slough and are frequently complicated by urethral fistulas and diverticuli [6]; however, these complications did not occur in our patient. The possible mechanisms resulting in skin necrosis are prolonged ischemic time, hematoma, and inadequate circulation. In practice, the wound edge oozing into the space between the prepuce and tunica albuginea cannot be drained effectively. The foreskin was gradually detached from the shaft deep fascia. Increased pressure compromised the circulation of prepuce and resulted in skin necrosis [7].

It is an agreed that the use of microsurgical technique for penile replantation can give better outcome when compared with nonmicrosurgical technique for penile preservation. Microscopic methods provide better circulation in wound healing and decrease the risk of complications [8]. However, such techniques require special equipment, instruments, and training which were not readily available. Efforts have been made therefore to develop a simple and standard technique of management that could be performed by any urologist [9].

The survival of the penis and its functions depend, no doubt, on the unique penile vascular system. It was reported that the viability of the amputated part proved to be surprising. Eight hours was the longest period between the incident and successful surgical repair [9]. The final cosmetic and functional results of the macroscopically replanted penis were gratifying. In patients with self-emasculatation, it is sometimes difficult to answer the question, if it was a failed suicide or a successful male self-amputation. In the early postoperative course, there remains an increased risk of self-mutilation of the replanted penis until the optimized therapy has been prescribed. Auto-aggressive actions can be prevented by adequate psychiatric medical therapy [10]. Penile replantation using the remaining stumps of the corpora cavernosa should be the first line therapy in patients with traumatic cosmetic aspects of the organ. Replantation

of the penis must be attempted when the amputated organ is recovered. A macrovascular technique is recommended, as it can be performed in any general hospital with an acceptable result.

### References

1. Schweitzer I. Genital self-amputation and the Klingsor syndrome. *Aust N Z J Psychiatry*. 1990; 24: 566-9.
2. Aboseif S, Gomez R, McAninch JW. Genital selfmutilation. *J Urol*. 1993; 150: 1143-6.
3. Romilly CS, Isaac MT. Male genital self-mutilation. *Br J Hosp Med*. 1996; 55: 427-31.
4. Ehrlich WS. Two unusual penile injuries. *J Urol*. 1929; 21: 239.
5. Park JK, Min JK, Kim HJ. Reimplantation of an amputated penis in prepubertal boys. *J Urol*. 2001; 165: 586-7.
6. Einarsson G, Goldstein M, Laungani G. Penile replantation. *Urology*. 1983; 22: 404-5.
7. Heymann AD, Bell-Thompson J, Rathod DM, Heller LE. Successful reimplantation of the penis using microvascular techniques. *J Urol*. 1977; 118: 879-80.
8. Sanger JR, Matloub HS, Yousif NJ, Begun FP. Penile replantation after self-inflicted amputation. *Ann Plast Surg*. 1992; 29: 579-84.
9. Bhanganada K, Chayavatana T, Pongnumkul C, et al. Surgical management of an epidemic of penile amputations in Siam. *Am J Surg*. 1983; 146: 376-82.
10. Yang JG, Bullard MJ. Failed suicide or successful male genital self-amputation? *Am J Psychiatry*. 1993; 150: 350-1.